

## MANAGEMENT OF ZYGOMA FRACTURE DUE TO MOTORCYCLE ACCIDENT WITH OPEN REDUCTION AND INTERNAL FIXATION TECHNIQUE AT RSD GUNUNG JATI CIREBON INDONESIA

### *(PENANGANAN FRAKTUR ZIGOMA AKIBAT KECELAKAAN SEPEDA MOTOR DENGAN TEKNIK REDUKSI TERBUKA DAN FIKSASI INTERNAL DI RSD GUNUNG JATI CIREBON INDONESIA)*

Tichvy Tammama<sup>1\*</sup>, M. Aldi Rohimawan<sup>2</sup>, Bambang Widjanarko<sup>3</sup>

<sup>1</sup>Department of Oral and Maxillofacial Surgery, Faculty of Dentistry,  
Universitas Jenderal Achmad Yani, Cimahi, West Java

<sup>2</sup>Faculty of Dentistry, Universitas Jenderal Achmad Yani, Cimahi,  
Indonesia

<sup>3</sup>Department of Oral and Maxillofacial Surgery, Gunung Jati Regional  
Hospital, Cirebon, Indonesia

\*Corresponding author

[tichvy@yahoo.com](mailto:tichvy@yahoo.com)

*JHDS.unjani.ac.id/jite*  
*Doi: 10.54052/jhds.*

**Article History**  
*Received: 00/00/20*  
*Accepted: 00/00/20*

### ABSTRACT

Zygoma fracture is part of midfacial trauma, which is usually caused by contact force, especially due to traffic accidents. Zygoma fracture can be accompanied by damage to soft tissue, teeth, and bone structure around the zygoma. A 20-year-old male patient came to the Emergency Room of RSD Gunung Jati Cirebon Indonesia with complaints of bleeding from the mouth for 8 hours due to a motorcycle accident. The patient was wearing a half-face helmet, and his face was hit the sidewalk. and had no history of being unconscious, nausea,

vomiting, nor bleeding from the nose and ears. On examination, the face appeared asymmetrical, accompanied by edema and an abrasion wound on the left cheek, a laceration on the tongue, and avulsion of teeth 33 and 42. The patient underwent a CBCT examination, with the results showing a fracture line on the left zygoma. The patient was treated by performing an Open Reduction Internal Fixation (ORIF) on the fracture and stitching the wound on the tongue. The fracture healed well, chewing and speech function improved, and the face returned to symmetry with good dental occlusion.

**Keywords:** fixation; fracture; ORIF; trauma; zygoma

### **ABSTRAK**

*Fraktur zygoma merupakan bagian dari trauma wajah bagian tengah yang biasanya disebabkan oleh kontak kekuatan, terutama akibat kecelakaan lalu lintas. Fraktur zygoma dapat disertai dengan kerusakan jaringan lunak, gigi, dan struktur tulang di sekitar zygoma. Seorang pasien laki-laki berusia 20 tahun datang ke IGD RSD Gunung Jati Cirebon dengan keluhan keluar darah dari mulut selama 8 jam akibat kecelakaan sepeda motor. Pasien menggunakan helm half face dan wajahnya terbentur trotoar. Tidak ada riwayat pingsan, mual, muntah, maupun keluar darah dari hidung dan telinga. Pada pemeriksaan, wajah tampak asimetris, disertai edema dan luka abrasi pada pipi kiri, laserasi pada lidah, dan avulsi gigi 33 dan 42. Pasien dilakukan pemeriksaan CBCT, dengan hasil terdapat garis fraktur pada zygoma kiri. Pasien dilakukan tindakan Open Reduction Internal Fixation (ORIF) pada fraktur dan dilakukan penjahitan luka pada lidah. Fraktur sembuh dengan baik, fungsi mengunyah dan berbicara membaik, dan wajah kembali simetris dengan oklusi gigi yang baik.*

**Kata kunci:** fiksasi; fraktur; ORIF; trauma, zygoma

## INTRODUCTION

Facial trauma often causes damage to tissues, teeth, and important bones such as the mandible, maxilla, zygoma, and the area around the eyes and nose.<sup>1</sup> Zygoma fractures as a part of facial trauma can be caused by accidental and non-traffic accident factors. Traffic accident is the main cause of zygoma fractures, accounting for more than 50% of cases, compared to non-traffic accident factors. The parts of the zygoma that often experience fractures are the sutures covering 86%, and the zygoma arch, covering 14%.<sup>2</sup>

Establishing the diagnosis of a zygoma fracture requires anamnesis, clinical examination, and appropriate radiological examination as well as a computed tomography (CT) scan.<sup>3</sup> When clinical evaluation indicates a fracture, it is also important to perform examinations related to function.<sup>1</sup>

The distribution of zygoma fracture types is classified by Manson et al and Remy H Blanchaert based on the segmentation pattern and displacement of the zygoma as seen through CT-Scan images. This classification is also related to the biomechanics of trauma incidents, causing fractures in patients with zygoma fractures.<sup>4</sup>

Fracture of the zygoma usually require treatment with the aim of improving function, aesthetics, and occlusion. Factors that influence the choice of zygoma fracture management depend on many factors such as cost, patient desire, the doctor's decision, skills, and the facilities available.<sup>5</sup> Open Reduction Internal Fixation (ORIF) is the gold standard in the management of maxillofacial fractures, including zygoma fracture.

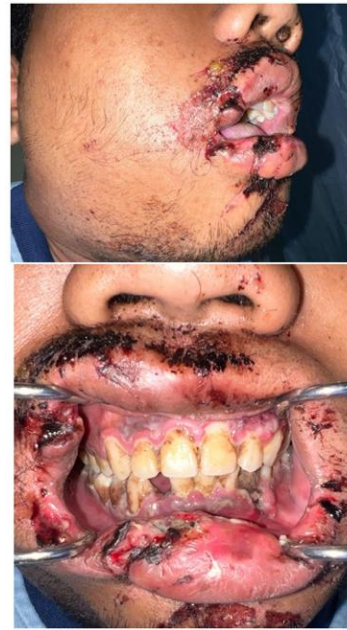## CASE REPORT

A 20-year-old male patient came to RSD Gunung Jati with complaints of bleeding from the mouth. Approximately 8 hours before entering the hospital, the patient was riding a motorcycle at moderate speed in the Kosambi area, suddenly fell asleep, and slipped so that he lost his balance and then fell, with his face hitting the asphalt first. The patient was wearing a half-face helmet. The patient was taken first to a private hospital in Cirebon, but no action was taken and then referred to the Emergency Installation of RSD Gunung Jati Indonesia for further treatment.

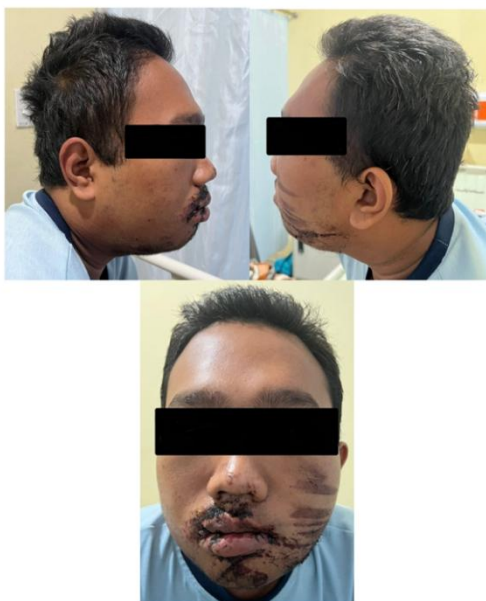Based on the results of the anamnesis it is discovered that the patient did not experience fainting, nausea, or

vomiting. The patient got bleeding from the mouth, but no history of bleeding from the nose and ears, and no history of alcohol poisoning.

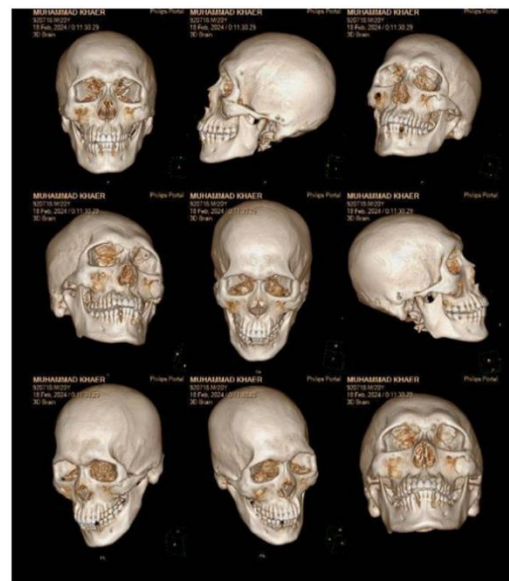
Extraoral examination found an asymmetrical face, edema with abrasion wounds around the left cheek, mouth, nose, and chin (Figure 1). Intraoral examination showed laceration wounds on the right commissure and tongue (Figure 2). The supporting examination performed on the patient was a CBCT examination, with the results showing fracture lines on the left zygoma (Figure 3). The diagnosis determined for the patient was a fracture of the left zygoma accompanied by lacerations on the right commissure and tongue area, with multiple abrasive wounds.



**Figure 2.** Intra oral image of the patient during initial examination.



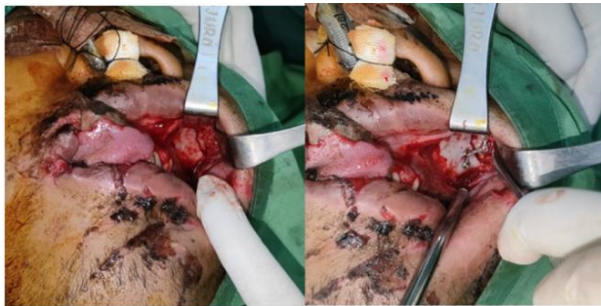**Figure 1.** Extra oral image of the patient during initial examination.



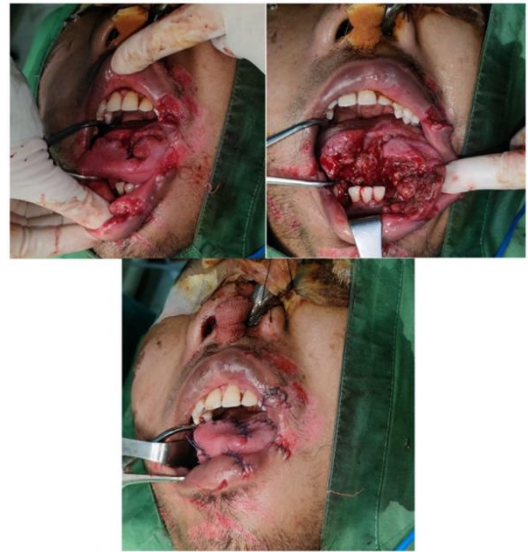**Figure 3.** Condition of the cranium from the CT Scan photo

The treatment performed was debridement and wound suturing as well as Open Reduction and Internal Fixation (ORIF), under general anesthesia. Treatment began with the preparation of the equipment, the operator, the assistant operator, and the patient. Furthermore,

aseptic and antiseptic actions were performed using povidone iodine in the area to be operated on. The patient's surgical area was covered using a sterile drape except for the mouth area. Next, the flap design was drawn intra-orally, then an incision is made using blade no. 15. The flap was then retracted using a raspatory until the fracture line was visible on the zygomatic bone. Then fractured bone was repositioned to its original position, then fixed with and installation of a 4-hole miniplate and screws around the fracture line (Figure 4). The flap was sutured back together using interrupted sutures. The next step was suturing the lacerations in the tongue and commissure area (Figure 5).

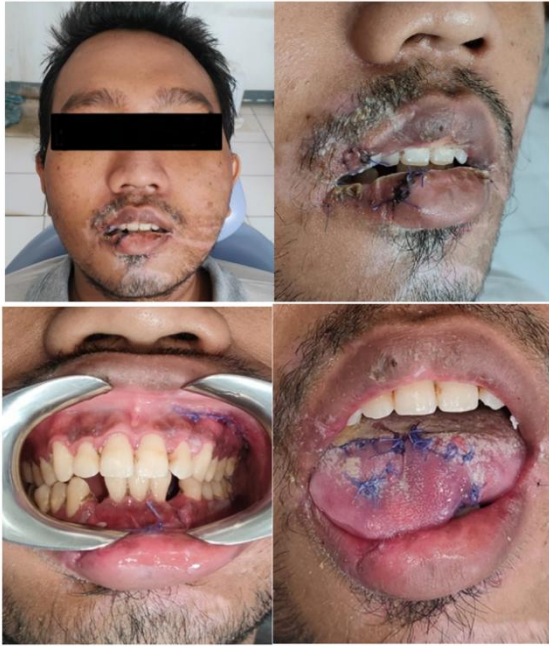

**Figure 4.** Repositioning and fixation of fractured bones.



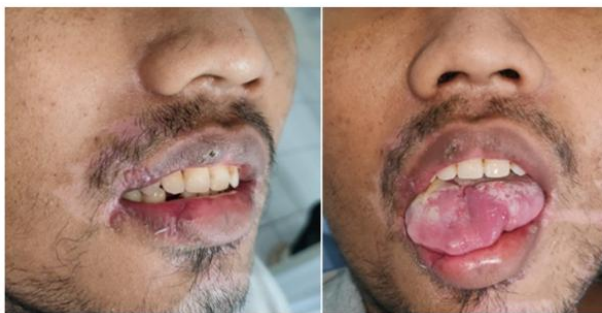**Figure 5.** suturing of lacerations on the tongue and commissures

The patient was instructed to have a liquid diet for the first week. The medications consumed by the patient were antibiotics and analgesics. The patient was instructed to maintain oral hygiene and had to return to RSD Gunung Jati for a check-up on the 7<sup>th</sup> day after the operation. The results showed that the laceration wound in the right commissure and tongue had closed, and no bleeding was found (Figure 6).



**Figure 6.** Patient condition during 1-week check-up

The patient then underwent suture removal (Figure 7). The patient then underwent a check-up again after one month to undergo ORIF removal.



**Figure 7.** Patient's condition on the 7th day after stitches were removed

## DISCUSSION

The zygomatic arch is the most lateral projection of the midface, contributing vital to the midface's structure and aesthetic appearance. This structure plays a key role because it absorbs and

dissipates traumatic forces away from the cranial base.<sup>6</sup> The zygoma articulates with the frontal, sphenoid, temporal, and maxillary bones and contributes significantly to the strength and stability of the midface. The forward projection of the zygoma causes it to be injured frequently.<sup>7</sup>

Zygoma fracture is a trauma that causes complete or incomplete zygomatic bone discontinuity due to contact force. Zygoma fractures are mostly caused by traffic accidents rather than non-traffic accidents. The etiology of the zygoma fracture in this case is due to trauma from a two-wheeled motor vehicle accident (MVA's).<sup>7,8</sup> There is also a retrospective study of the incidence of accidents in zygoma fractures in West Karnataka, India, stating that the most common trauma causing zygoma fractures is car accidents, which is 36%, being hit by a car, 32%, motorcycle accidents 23%, and falling off a motorcycle 9%.<sup>8</sup>

Classification of zygoma fractures according to Manson et al and Remy H Blanchaert is classified into low-energy and high-energy. Low-energy zygoma fractures indicate that there is minimal or no displacement of bone fragments and/or no comminution of the fracture fragments. The fracture area is usually seen at the zygomatico-frontal suture. This area is stable when reduced, so fractures involving

this area can be treated either conservatively or with minimal fixation if necessary.<sup>9</sup>

As for high-energy fractures, comminution, lateral displacement, and segmental fractures of the zygomatic arch will be obtained so that the bone fragments become unstable. Other effects on soft tissue include extensive edema.<sup>9</sup>

Zygomatic fractures are not life-threatening and are usually treated after more serious injuries are stabilized and swelling has resolved 4 to 5 days after injuries.<sup>7</sup>

The diagnosis of zygomatic fractures is usually established by history, clinical and radiological examination.<sup>7,10</sup> In history examination, the nature, force, and direction of the injuring blow should be determined from the patient and any witnesses. Initial evaluation of the patient with a zygomatic fracture includes documentation of the bony injury and the status of surrounding soft tissue. Ecchymosis and edema are the most common early clinical signs of zygomatic injuries. Depression of the malar eminence and infraorbital rim produce flattening of the cheek. Subconjunctival hemorrhage is often noted. Lacerations in the facial region should lead the surgeon to suspect underlying fracture.<sup>7</sup>

Radiographs are helpful for

confirmation of the extent of the injury and for medicolegal documentation. CT scan of the facial bones, in axial and coronal planes, is standard for all patients with suspected zygomatic fractures.<sup>7,10</sup> Radiological examination in this case was carried out using 3D CT for three-dimensional visualization of the facial fracture area. 3D CT is a medium that is more acceptable to surgeons with greater interpretation accuracy than conventional axial CT scans.<sup>11</sup> CT is the gold standard for radiographic evaluation of zygomatic fractures. Axial and coronal images are obtained to define fracture patterns, degree of displacement, and comminution and to evaluate the orbital soft tissues. Specifically, CT scans allow for visualization of the buttresses of the midfacial skeleton: nasomaxillary, zygomaticomaxillary, infraorbital, zygomaticofrontal, zygomaticosphenoid, and zygomaticotemporal buttresses.<sup>7</sup>

Treatment of zygomatic fractures must be based on a complete preoperative evaluation.<sup>7</sup> Whenever facial structures are injured; treatment must be directed toward maximal rehabilitation of the patient. For facial fractures, treatment goals include rapid bone healing; return of normal ocular, masticatory, and nasal functions; restoration of speech; and an acceptable facial and dental esthetic result. During the

treatment and healing phases, it is also important to minimize the adverse effect on the patient's nutritional status and achieve treatment goals with the least amount of discomfort and inconvenience possible.<sup>12</sup>

To achieve these goals, the following basic surgical principles should serve as a guide for treatment of facial fractures: reduction of the fracture (restoration of the bony segments to their proper anatomic location) and fixation of the bony segments to immobilize segments at the fracture site. In addition, the preoperative occlusion must be restored, and any infection in the area of the fracture must be eradicated or prevented.<sup>12</sup>

In zygomatic fracture, repair should take place as quickly as possible before scarring and setting of bony fragments into their posttraumatic positions begins. Because significant facial edema disguises aesthetic deformities and increases exposure difficulty, fracture repair should ideally be performed within 2 to 3 days of the initial injury.<sup>6</sup>

Successful treatment requires reestablishing occlusion and restoration of facial buttresses and prominences, as well as recontouring bony cavities. Several methods have evolved to repair zygomatic fractures. However, closed reduction may be adequate for simple, low-velocity

injuries of the zygoma that are nondisplaced or minimally displaced and remain stable after initial reduction.<sup>6,13</sup> Open reduction and internal fixation (ORIF) should be the approach of choice for fractures that are comminuted or are likely to be unstable after reduction.<sup>6</sup> Open Reduction Internal Fixation (ORIF) is a surgical procedure to manipulate broken bone fragments or return them to their original position.<sup>14</sup> Internal fixation involves the use of plates and screws until solid bone healing occurs.<sup>15</sup> Typically, low-profile titanium mini plates are used to fixate the fractured bone segments, working to repair fractures from laterally to medially and from stable to mobile segments.<sup>6</sup>

Regardless of the type of facial fracture or the surgical approach used, the initial procedure should be to place the teeth in the proper occlusion and then appropriately reduce the bony fractures. Bony repair should also precede soft tissue repair.<sup>12</sup>

Although complications of zygomatic fractures are uncommon, the surgeon must recognize their signs and symptoms to provide appropriate care. Complications may occur in the early postoperative period or may become manifest only later in recovery, such as infraorbital paresthesia, malunion and



assymetry, enophthalmos, diplopia, traumatic hyphema, traumatic optic neuropathy, superior orbital fissure syndrome, and retrobulbar hemorrhage.<sup>6,7</sup>

In the present case, treatment was carried out using the ORIF technique using a four-hole plate and screws to return the fracture fragments to their original position, and the laceration wounds are sutured properly. A soft diet is recommended to prevent the distraction of fractures by muscle contraction. The fracture healed well, chewing and speech function improved, and the face returned to symmetry with good dental occlusion, and no complications were found in the patient.

## CONCLUSION

Zygoma fracture is a trauma that causes complete or incomplete bone discontinuity due to contact forces that are usually caused by traffic accidents. Zygoma fractures are often found due to motor vehicle accidents. Before determining the treatment of zygoma fractures, a subjective and objective examination is required first. ORIF is one technique that can be performed to return fracture fragments to their original position.

## CONFLICT OF INTEREST

There is no conflict of interest in

the process of making this case report.

## ACKNOWLEDGEMENT

We would like to thank to the professionals in RSD Gunung Jati (RSGJ) Cirebon for giving permission to carry out and assist with the case report, and everyone who contribute to preparation of the paper.

## REFERENCES

1. Tucker MR, Assael LA. Management of facial fractures. In: Peterson LJ. Contemporary oral and maxillofacial surgery, 4<sup>th</sup> Ed. St. Louis: Mosby Co.; 2003. p.527-37.
2. Manolidis, et al. 2017. Classification and surgical management of orbital fractures: experience with 111 orbital reconstructions. [online] Available at: <https://www.ncbi.nlm.nih.gov/pubmed/?term=classification+and+surgical+management+of+orbital+fractures%3A+experience+with+111+orbital+reconstruction>.
3. Dewi Yuri Lestari, Al Hafiz, Effy Huriyati. Diagnosis dan Penatalaksanaan Fraktur Le Fort I-II disertai Fraktur Palatoalveolar Sederhana. Jurnal Kesehatan Andalas. 2018;7:78-84
4. Fonseca, R., Marciani, R., Turvey, T., Carlson, E., Braun, T. 2009. Oral and

- maxillofacial surgery. St. Louis: Mo.: Saunders Elsevier.
5. Chalya PL, Mchembe M, Mabula JB, Kanumba ES, Gilyoma JM. Etiological spectrum, injury characteristics and treatment outcome of maxillofacial injuries in a Tanzanian teaching hospital. *J Trauma Manag Outcomes*. 2011; 5(7):1–6.
  6. Bergeron JM, Raggio BS. Zygomatic Arch Fracture. National Library of Medicine. 2024. <https://www.ncbi.nlm.nih.gov/books/NBK549898/> [diakses: 1 Juni 2025]
  7. Miloro M, Ghali GE, Larsen P, Waite P. *Peterson's Principles of Oral and Maxillofacial Surgery*. 3<sup>rd</sup> ed. 2011. Connecticut: PMPH-USA. p. 465-479.
  8. Singh, et al. 2014. Incidence Zygoma and Mandibular Fracture in West Karnataka. *IJO CR*, v.3(7).
  9. Olate, S., Lima, S., Sawazaki, R., Moreira, R., de Moraes, M. 2011. Variables Related to Surgical and Nonsurgical Treatment of Zygomatic Complex Fracture. *Journal of Craniofacial Surgery*, 22(4); p. 1200-1202.
  10. Dolan RW. Zygomatic complex and internal orbital fractures. In: Dolan RW. *Facial plastic reconstruction, and trauma surgery*. 2004. New York: Marcel Dekker.
  11. Bailey JS, Goldwasser MS. Management of zygomatic complex fracture, In: Miloro M. *Peterson's principles of oral and maxillofacial surgery*. 2nd Ed. 2004. London: BC Decker Inc; H. 446,457.
  12. Hupp JR, Ellis E, Tucker MR. *Contemporary Oral and Maxillofacial Surgery*. 7<sup>th</sup> ed. 2019. Philadelphia: Elsevier. p. 527-529.
  13. Strong EB, Gary C. Management of Zygomaticomaxillary Complex Fractures. *Facial Plast Surg Clin North Am*. 2017 Nov;25(4):547-562.
  14. Gellrich NCB, Zimmerer RM. Surgical management of maxillary and zygomatic fractures. *Maxillofacial Surgery*. 3rd ed. 2017(1): 93-132. Churchill Livingstone.
  15. Smeltzer, Bare. (2012). *Buku Ajar Keperawatan Medikal Bedah Brunner dan Suddarth* (Ed.8, Vol. 1,2). Jakarta: EGC.