

IMPACTION OF PERMANENT CANINES DUE TO PERSISTENCE OF PRIMARY TEETH ON DIFFERENT RADIOGRAPHIC IMAGES: CASE REPORT

(IMPAKSI GIGI KANINUS PERMANEN AKIBAT PERSISTENSI GIGI SULUNG PADA GAMBARAN RADIOGRAF YANG BERBEDA: LAPORAN KASUS)

Ratna Trisusanti^{1*}

¹Department of Dental Radiology, Faculty of Dentistry, Universitas Jenderal Achmad Yani, Cimahi, Indonesia

JHDS.unjani.ac.id/jite
Doi:
10.54052/jhds.v5n1.p51-
58.

Article History
Received: 18/03/2025
Accepted: 20/04/2025

ABSTRACT

A 24-year-old male patient came to the Unjani Teaching Dental and Oral Hospital complaining of a disturbing residual root of the upper right front tooth and wanted to be extracted. Still, when a periapical radiograph was taken, it was found that the residual root of the tooth was a primary tooth that had not yet fallen out because there was a radiopaque picture resembling the impaction of a permanent canine tooth at the apex of the tooth. The patient never felt pain, and the complaint had never been treated before, so the patient wanted treatment to eliminate the complaint. Further supporting examination is needed, such as an occlusal radiography examination, which plays an important role in seeing the position of impaction of permanent canines in the upper and lower jaws and serves as a basis for determining the treatment plan to be carried out. This case report aims to describe the eruption disorder in the form of impaction of maxillary permanent canines due to the persistence of residual roots of primary teeth and to see in detail the position of the impaction from radiographic images of occlusal photos

in the upper jaw. This case shows that the persistence of primary teeth can cause abnormalities in the direction of growth of permanent teeth into tooth impaction abnormalities found from radiographic images.

Keywords: canine; impaction; persistence; radiography

ABSTRAK

Pasien laki-laki usia 24 tahun datang ke Rumah Sakit Gigi dan Mulut Pendidikan Unjani dengan keluhan terdapat sisa akar gigi depan kanan atas yang mengganggu dan ingin dilakukan pencabutan, tetapi pada saat dilakukan foto radiografi periapikal ditemukan bahwa sisa akar gigi tersebut merupakan gigi sulung yang belum tanggal, karena terdapat gambaran radiopak menyerupai impaksi gigi kaninus permanen di ujung apeks gigi tersebut. Pasien tidak pernah merasakan sakit, dan keluhan tersebut belum pernah dilakukan perawatan apapun sebelumnya, sehingga pasien ingin dilakukan perawatan agar keluhannya tersebut dihilangkan. Pemeriksaan penunjang lanjutan yang dibutuhkan adalah pemeriksaan radiografi oklusal, yang memegang peranan penting dalam melihat posisi impaksi gigi kaninus permanen pada rahang atas maupun rahang bawah, yang juga berfungsi sebagai dasar dalam menentukan rencana perawatan yang akan dilakukan. Laporan kasus ini bertujuan untuk menggambarkan gangguan erupsi berupa impaksi kaninus permanen rahang atas akibat persistensi sisa akar gigi sulung serta melihat secara detail posisi impaksi dari gambaran radiografi foto oklusal pada rahang atas. Kasus ini menunjukkan bahwa persistensi gigi sulung dapat menyebabkan terjadinya abnormalitas arah pertumbuhan gigi permanen menjadi kelainan impaksi gigi yang dapat ditemukan dari gambaran radiografi.

Kata Kunci: impaksi; kaninus; persistensi; radiograf

INTRODUCTION

Growth in a person includes systematic, progressive, and continuous changes between systems and organs from birth to maturity or maturity.^{1,2} The process of tooth growth and development is divided into three stages, namely the tooth development stage, the tooth calcification stage, and the tooth eruption stage.³

The 2018 report on the types of dental diseases and disorders in Padang City shows that the category of developmental and eruption disorders is second, with 8897 reports, where dental persistence cases are the main problem of this category. Tooth persistence is the failure of primary teeth to erupt correctly while the replacement permanent teeth have erupted.^{4,5}

Teeth that are often impacted are maxillary and mandibular third molars, maxillary canines, and mandibular premolars, where the percentage of maxillary canine impaction cases is 0.8-2.8%, with one of the causes being the persistence of primary teeth.⁶

Radiographic examination plays a vital role in every stage of case management in dentistry. The radiographic examination can project areas that are not clinically visible, such as tooth impaction, and increase the contribution of radiographic diagnostic information because the radiographic examination has now been

considered a follow-up or supporting examination of clinical examination. Radiographic procedures have the ALARA (As Low As Reasonably Achievable) principle. More than 80% of dental cases require radiographic examination to manage oral and dental diseases.^{7,8}

As in this case report, the 24-year-old patient did not realize that the root remnant in his maxillary right canine tooth was a persistent primary tooth. It was only discovered when the patient took a periapical radiograph of the residual root of the canine tooth, where during radiographic interpretation, it was seen that there was a transverse radiopaque image at the apex of the residual root of the canine tooth resembling the impaction of the maxillary right permanent canine tooth, so a radiographic photo was retaken with the occlusal photo technique to see the state of the impacted permanent canine tooth as support in determining treatment.

CASE REPORT

The 24-year-old male patient complained of root residue on the upper right front tooth that had been bothering him since \pm 5 years ago. The patient admitted that the tooth had a large cavity and eventually broke, but currently, the tooth is not painful. It just interferes with appearance and makes food easily stuck.

The patient was a first-time visitor to the dentist and had never been treated before. The patient also admitted that an x-ray had never been taken before, so the patient wanted the tooth to be extracted and needed a radiographic image to support the treatment.

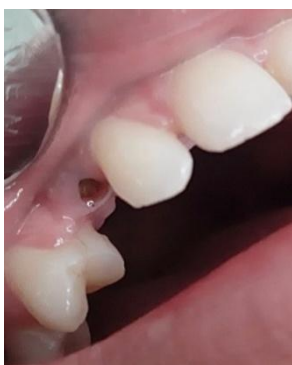

Figure 1. Clinical picture of residual root persistence of tooth 53.

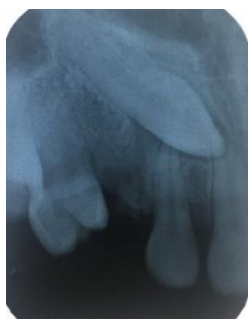

Figure 2. Periapical radiograph of the remaining root of tooth 53.

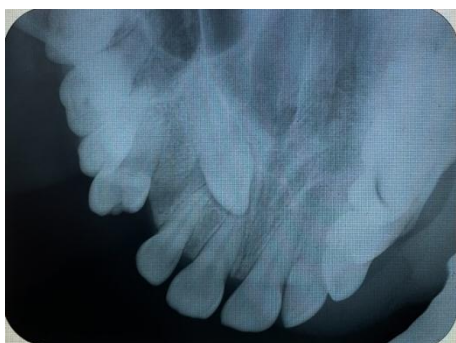


Figure 3. Occlusal radiographic image of tooth 13 impaction.

There is a radiopaque image on the palate resembling the structure of an unerupted tooth 13 in a horizontal position, where the crown is close to the median line in the periapical area of teeth 11 and 12, while the root is in the periapical area of tooth 14 and posteriorly directed. The surrounding dental follicles appeared within normal limits, with the teeth positioned closer to the palate surface.

DISCUSSION

A 24-year-old male patient came to the Unjani Teaching Dental and Oral Hospital complaining of root residue on the upper right front tooth that had been bothering him since \pm 5 years ago. The history of systemic disease and family history of the patient was denied. The patient came to the dentist for the first time and had never been treated. The patient also admitted that no X-rays had been taken before. On extraoral examination, there were no abnormalities on the patient's face or neck. On intraoral examination, the remaining root of the right regio canine tooth was untenable and indicated for extraction.

When a periapical radiograph was taken, it showed that the remaining root of the tooth was a primary tooth that had not yet fallen out because there was a radiopaque picture resembling the

impaction of a permanent canine tooth at the apex of the tooth, with the interpretation results being that there was a picture of a crown that disappeared up to 2/3 of the root in tooth 53 with one root resembling the remaining root and in the periapical tooth 53 there was a radiolucent picture with unclear and indistinct boundaries resembling an abscess, accompanied by a transverse radiopaque picture from the tip of the root of tooth 11 to the tip of the root of tooth 14 resembling the impaction of tooth 13.

Furthermore, the patient was recommended to perform occlusal radiography to see and evaluate the impaction of maxillary permanent canines. The occlusal radiography photo technique begins with preparing the tools and materials for use in the form of x-rays, films, and aprons. Previously, the patient was invited to remove jewellery on the head and neck to prevent interference with interpreting occlusal photos. The patient's head is positioned until the ala-tragus line is parallel to the floor by gently biting the film placed in the sagittal plane with the side of the tube towards the maxilla. The X-ray tube is centered over the patient so that the beam reaches the nasal bridge at an angle of 65-70° to the film.^{9,13}

The interpretation of occlusal radiographs revealed a radiopaque image on the palate resembling the structure of an unerupted

tooth 13 in a horizontal position, where the crown was close to the median line in the periapical area of teeth 11 and 12, while the root was in the periapical area of tooth 14 and pointed posteriorly. The surrounding dental follicles appeared within normal limits, with the teeth positioned closer to the palate surface. In this case, the suspected radiodiagnosis impacted class I level C tooth 13 of the Archer classification. In this case, the treatment plan is to extract the remaining root of tooth 53, which is persistent, and perform orthodontic treatment to pull the impacted tooth 13 back to the proper maxillary arch.

Impaction, as in this case, can occur due to lack of space for eruption, dense bone or thick, soft tissue, chronic infection, and developmental abnormalities. The wrong eruption path of the permanent teeth is most likely caused by the failure of resorption of the deciduous teeth, which results in persistence. Another factor influencing this persistence is the absence of permanent tooth seeds due to disorders in the initiation stage in the form of cells that cannot proliferate or nutritional disorders in children.^{5,11,12}

In this case, the patient's next visit was an extraction with an infiltration technique using pehacaine anesthesia. Before the procedure, before taking action, informed consent was given to the patient,

and the condition of the tooth and the actions to be taken were explained. After the extraction, the patient was given post-extraction instructions such as biting a tampon for 1 hour, not drinking hot water first, not spitting and gargling frequently, and not playing and sucking the wound area to avoid post-extraction complications. After that, the patient was instructed to come back 1 week later for post-action control.

In the management, the preparation of tools and materials was carried out, followed by the preparation of the operator and patient. Next, the first was to perform anesthesia preceded by aseptic and antiseptic measures.

The operator is positioned in front of the patient, with the patient sitting on the dental chair upright and relaxed. The extraction forceps of the remaining root of the maxillary canine tooth are held using the right hand, and with the left hand, the operator fixes the gingival area of the tooth. Next, the extraction forceps are applied to tooth 53, then a slight palatal reduction is made, followed by a buccal reduction, and the tooth is pulled out of the socket. Once the tooth is extracted, check the sockets and massage the gingiva before the patient bites down on a sterile tampon with povidone-iodine.¹⁴

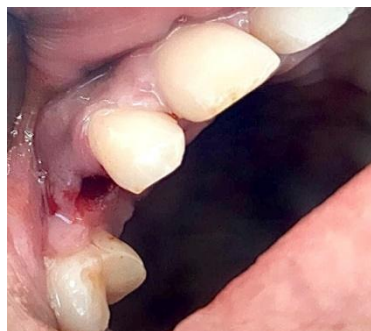

Figure 4. Clinical picture after extraction of the persistent residual root of tooth 53.

The third visit was at the time of control 1-week post-extraction. It was seen that the tooth socket had closed, was in good gingival condition, and had no post-extraction complaints in the area. So, further treatment can be carried out, where the patient can be given orthodontic treatment to pull the impaction of permanent canine teeth out to the maxillary dental arch.

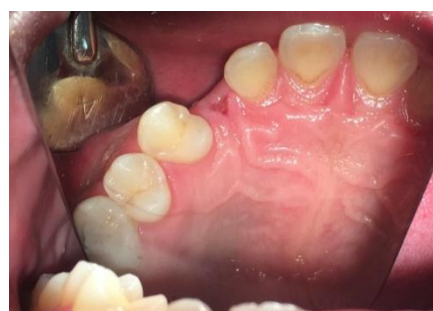

Figure 5. 1-week post-extraction clinical picture.

CONCLUSION

Radiographic examination is a beneficial supporting examination in dental practice. It is a necessary tool for finding phenomena that are not known clinically by eye visualization, can detect severity, and is

a diagnostic determinant for the establishment of a treatment plan to be carried out, especially for diseases or abnormalities in the oral cavity.

As in the case which has found the impaction of permanent canines due to the persistence of primary canines that are not known by the patient, after further supporting examination in the form of occlusal radiography, the action taken is to extract the remaining roots of tooth 53 which will then be fitted with a fixed orthodontic device to pull the impaction of permanent teeth 13 back into the maxillary dental arch.

CONFLICT OF INTEREST

No potential conflict of interest was reported during research and in writing this article.

ACKNOWLEDGEMENT

Our thanks go to the professionals who assisted in the research and preparation of the paper.

REFERENCES

1. Sudirjo E, Alif MN. Konsep perkembangan dan pertumbuhan fisik dan gerak manusia. Ed.1. Sumedang: UPI Sumedang Press; 2018. hal. 62.
2. Yoga A, Umiyarni D, Kusnandar. Hubungan jenis kelamin, aktifitas fisik dan status gizi dengan kesegaran jasmani anak sekolah dasar. Kesmasindo 2014; 7(1): 31-38.
3. Mokhtar M. Dasar-dasar orthodonti: Pertumbuhan dan perkembangan kraniofasial. Medan: Bina Insani Pustaka; 2002. hal. 45-224.
4. Nur RA. Hubungan pengetahuan ibu tentang pertumbuhan gigi dengan kasus persistensi pada anak usia 7-11 tahun di wilayah kerja Puskesmas Andalas. Padang: Universitas Andalas. 2019.
5. Noorharsanti, T Aprilia, EM Setiawati, Mexitalia. Hubungan jumlah gigi susu dengan pola makan anak usia 9-24 bulan. Skripsi. FKG Undip. 2004.
6. Iswanto H, Titien I, Rahardjo. Penatalaksanaan impaksi kaninus kiri atas dengan posisi horisontal pada anak. Yogyakarta: Universitas Gadjah Mada. 2015; 1(2): 92-98.
7. Anggara A, Iswani R, Darmawangsa. Perubahan Sudut Penyinaran Vertikal Pada Bisecting Technique Radiography Terhadap Keakuratan Dimensi Panjang Gigi Premolar Satu Atas. J B-Dent 2018; 5(1): 1-8.
8. Supriyadi. Pedoman Interpretasi Radiografi Lesi-Lesi Di Rongga Mulut. J. K. G Unej 2012; 9(3): 134-139.

9. White Stuart, Pharoah M. Oral Radiology Principles and Interpretation. 7th ed. Canada: Elsevier; 2014. 354-357.
10. RF Ramadhani. Gambaran epidemiologis gigi sulung persistensi: kajian pada anak usia 7-12 tahun di SDN Tomang 01 Pagi Jakarta Barat. Skripsi. FKG-Trisakti 2018.
11. Taran PK, Olmez A. Prevalence, distribution, and condition of persistent primary teeth in children and adolescents. International Journal of Pedodontic Rehabilitation. 2019 Jul-Dec; 4(2): 50-54.
12. Aktan AM, Kara I, Sener I, Berekat C, Saih C, Kirtay M, Ciftci ME, Arici N. An evaluation of factor associated with persistent primary teeth. European Journal of Orthodontics. 2011: 1-5.
13. Suntana MS, Trisusanti R. Kista Dentigerous Pada Impaksi Gigi Kaninus Rahang Atas Yang Diamati Menggunakan Pemeriksaan Radiograf Rutin (Case Report: Kista Dentigerous On Impaction Of Caninus Maxilaris Using Routine Radiograph Examination). Medika Kartika : Jurnal Kedokteran dan Kesehatan. 2020
14. Septiyani A, Chandra M, Ruslin M. Penatalaksanaan impaksi gigi kaninus rahang atas. Dentofasial Jurnal Kedokteran Gigi. 2012.