

## PROTECTIVE EFFECT OF PURPLE SWEET POTATO (*Ipomoea batatas L.*) EXTRACT ON GENTAMYCIN-INDUCED WISTAR RATS LIVER CELLS

(EFEK PERLINDUNGAN UBI JALAR UNGU (*Ipomoea batatas L.*) EKSTRAK PADA SEL HATI TIKUS WISTAR YANG DIINDUKSI GENTAMYCIN)

Dian Anggraeny<sup>1\*</sup>, Eka Noneng Nawangsih<sup>2</sup>, Moch Falah Arrafi<sup>3</sup>

<sup>1</sup>Department of Histology, Faculty of Medicine, Universitas Jenderal Achmad Yani, Cimahi, West Java, Indonesia

<sup>2</sup>Department of Microbiology, Faculty of Medicine, Universitas Jenderal Achmad Yani, Cimahi, West Java, Indonesia

<sup>3</sup>Faculty of Medicine, Universitas Jenderal Achmad Yani, Cimahi, West Java, Indonesia

\*Corresponding author

[dian.anggraeny@lecture.unjani.ac.id](mailto:dian.anggraeny@lecture.unjani.ac.id)

JHDS.unjani.ac.id/jite  
Doi: 10.54052/jhds.

### Article History

Received: 00/00/20

Accepted: 00/00/20

### ABSTRACT

Gentamicin is a commonly used antibiotic for treating aerobic gram-negative bacterial infections. However, it has hepatotoxic effects that can damage liver hepatocyte cells through the generation of free radicals. Antioxidant compounds are needed to neutralize these free radicals and prevent cellular damage. Purple sweet potato (*Ipomoea batatas L.*) is known to be rich in anthocyanins, which possess antioxidant properties. This study aimed to determine the effect of ethanol extract of purple sweet potato (*Ipomoea batatas L.*) on liver histopathology in Wistar rats exposed to gentamicin. This was a laboratory experimental study using 24 male Wistar rats divided into four groups (n=6 per group). Group K1 served as a negative control. Group K2 was a positive control, induced with gentamicin 80

mg/kgBW/day subcutaneously for 8 days. Group P1 received 200 mg/head of purple sweet potato ethanol extract orally along with gentamicin for 8 days. Group P2 received 400 mg/head of the extract orally along with gentamicin for 8 days. Liver damage was assessed using histopathological examination and scored based on the Manja Roenigk criteria. Data were analyzed using one-way ANOVA followed by Tukey's post hoc ( $p < 0.05$ ). Results are the highest degree of hepatocyte damage was observed in Group K2. Group P1 showed a significant reduction in liver cell damage compared to Group K2 ( $p < 0.05$ ), indicating hepatoprotective activity at a dose of 200 mg/head. In contrast, Group P2 showed a higher damage score than Group P1, suggesting reduced effectiveness at the higher dose. Conclusion is ethanol extract of purple sweet potato at a dose of 200 mg/head demonstrated better hepatoprotective effects compared to a dose of 400 mg/head in Wistar rats exposed to gentamicin.

**Keywords:** gentamicin; hepatic; purple sweet potato extract

### **ABSTRAK**

*Gentamisin merupakan antibiotik yang umum digunakan untuk mengobati infeksi bakteri gram negatif aerob. Namun, obat ini memiliki efek hepatotoksik yang dapat merusak sel hepatosit hati melalui pembentukan radikal bebas. Oleh karena itu, senyawa antioksidan diperlukan untuk menetralkan radikal bebas tersebut dan mencegah kerusakan sel. Ubi jalar ungu (Ipomoea batatas L.) diketahui kaya akan antosianin yang memiliki sifat antioksidan. Penelitian ini bertujuan untuk mengetahui pengaruh ekstrak etanol ubi jalar ungu (Ipomoea batatas L.) terhadap gambaran histopatologi hati tikus Wistar yang dipapar gentamisin. Penelitian ini merupakan studi eksperimental laboratorium dengan menggunakan 24 ekor tikus Wistar jantan yang dibagi menjadi empat kelompok ( $n=6$  per kelompok). Kelompok K1 sebagai kontrol negatif. Kelompok K2 sebagai kontrol positif, diinduksi*

*dengan gentamisin 80 mg/kgBB/hari secara subkutan selama 8 hari. Kelompok P1 diberi ekstrak etanol ubi jalar ungu sebanyak 200 mg/ekor secara oral bersamaan dengan gentamisin selama 8 hari. Kelompok P2 diberi ekstrak sebanyak 400 mg/ekor secara oral bersamaan dengan gentamisin selama 8 hari. Kerusakan hati dinilai berdasarkan pemeriksaan histopatologi dan diberi skor menggunakan kriteria Manja Roenigk. Data dianalisis menggunakan uji ANOVA satu arah yang dilanjutkan dengan uji post hoc Tukey ( $p < 0,05$ ). Hasil penelitian menunjukkan bahwa tingkat kerusakan sel hati tertinggi terjadi pada Kelompok K2. Kelompok P1 menunjukkan penurunan signifikan pada kerusakan sel hati dibandingkan Kelompok K2 ( $p < 0,05$ ), yang menunjukkan aktivitas hepatoprotektif pada dosis 200 mg/ekor. Sebaliknya, Kelompok P2 menunjukkan skor kerusakan yang lebih tinggi dibandingkan Kelompok P1, mengindikasikan efektivitas yang menurun pada dosis yang lebih tinggi. Kesimpulan: Ekstrak etanol ubi jalar ungu pada dosis 200 mg/ekor menunjukkan efek hepatoprotektif yang lebih baik dibandingkan dosis 400 mg/ekor pada tikus Wistar yang terpapar gentamisin.*

***Kata kunci:*** ekstrak ubi jalar ungu; gentamicin; hepatic

## INTRODUCTION

The liver is an organ that plays an essential role in the metabolism, biotransformation, and detoxification of various types of drugs, making it susceptible to damage.<sup>1</sup> Several factors, such as the type, dose, and duration of exposure to toxic substances, influence liver damage due to toxic substances.<sup>2</sup> Aminoglycosides are antibiotics often used to treat aerobic gram-negative bacterial

infections.<sup>3</sup> Gentamicin is one of the most nephrotoxic aminoglycoside antibiotics and has hepatotoxic effects. Gentamicin has hepatotoxic effects because it is a xenobiotic or is foreign to the body.<sup>4</sup> Gentamicin can increase oxidative stress and free radical activity and inhibit the antioxidant defense system in the liver, resulting in increased production of Reactive Oxygen Species (ROS). ROS will damage proteins, lipid membranes, and

nucleic acids, which will ultimately cause toxicity, dysfunction, and liver cell damage and necrosis.<sup>5,6</sup> Antioxidant compounds are needed to capture and neutralize free radicals to avoid cell damage from free radicals. Purple sweet potato (*Ipomoea Batatas L.*) is a sweet potato plant with high levels of antioxidants.<sup>7</sup> The benefits of purple sweet potatoes (*Ipomoea Batatas L.*) include being anti-inflammatory, antimutagenic, free radical scavengers, and antidiabetic because they contain the highest antioxidants in the form of anthocyanins compared to other types of colored sweet potatoes.<sup>8</sup>

In research conducted by Susianti (2013), mice induced by gentamicin 80 mg/kg BW intraperitoneally for 10 days affected the histopathological picture of white mice's liver, lungs, and testes (*Rattus norvegicus*). The liver organ experienced hepatocellular changes, dilated and compacted sinusoids, accompanied by bleeding.<sup>9</sup> In addition, in research conducted by Grace et al. (2016) regarding the administration of purple sweet potato extract at a dose of 200 mg/head induced by gentamicin at a dose of 60 mg/kg BW on the histopathological picture of the kidneys intraperitoneally for 7 and 10 days, showed that administration of purple sweet potato extract for 7 days in Wistar rats that had been induced by gentamicin could protect

and regenerate tubular epithelial cells, necrosis and small hydropic degeneration compared to the positive control group.<sup>10</sup>

Based on the description above, the researcher is interested in knowing whether the administration of purple sweet potato ethanol extract (*Ipomoea Batatas L.*) has a protective effect in preventing liver cell damage in Wistar rats induced by gentamicin. This study aims to determine the effect of purple sweet potato ethanol extract (*Ipomoea Batatas L.*) on the liver of Wistar rats exposed to gentamicin.

## METHOD

This study is an experimental laboratory study. The design used is a randomized post-test-only control group design, where the study is conducted randomly with a final test and a control group.

This study used the ethanol extract of purple sweet potato tubers as the object. The ethanol extract of purple sweet potato was manufactured at the Department of Biochemistry, Faculty of Medicine, Universitas Jenderal Achmad Yani.

The subjects in this study were 24 white rats (*Rattus norvegicus*) with Wistar strains of the same body weight and age, so they had homogeneity. To conduct the study, the rats must meet the inclusion criteria: male rats, aged 6-8 weeks,

weighing 200-300 grams, actively moving, with clean and smooth fur, and no anatomical abnormalities were found. Rats that meet the exclusion criteria cannot be studied. The exclusion criteria are that the experimental animals experience a weight loss of more than 10% during the adaptation period.

In this study, the tools used to make purple sweet potato ethanol extract were macerators and rotary evaporators. The other tools were divided into two: tools for mice and preparation. The tools used to treat mice were 1 ml syringes, gastric tubes, and gloves. The tools for mouse surgery were disposable syringes, scalpels, tissue scissors, wax pads, and gloves. The tools used to make histopathology preparations were knives, gauze bags, gauze, fixation bottles, dehydration bottles, automatic dehydration tools, frozen cutting tools, microtomes, object glasses, heating cabinets, tissue staining tools, binocular microscopes, cover glasses, research materials used to prepare were 10% formalin buffer solution, graded alcohol, Xylol solution, paraffin, aquades, and Hematoxylin-Eosin dye.

The process of making purple sweet potato extract is as follows: First, the purple sweet potato was cleaned with clean water and peeled. The purple sweet potato flesh is thinly sliced, mixed with 96% ethanol, and

then mashed. Furthermore, maceration is carried out in a closed container for 24 hours. This mixture is then filtered with Whatman filter paper, and the filtrate obtained is evaporated with a rotary evaporator until a thick extract is obtained.

11

All rats were allowed to adapt for 7 days in a rat cage with a room temperature of 22 ° C and adequate ventilation. The cage used was 120 x 70 cm with a height of 60 cm or an area of 1,800 cm<sup>2</sup> and filled by six rats per cage with the hope that all rats would feel comfortable in their new cage. During the study, rats were given food and drinking water.

On the 8th day, male Wistar rats were randomly divided into four groups. K1 (Negative control group) Wistar rats received standard feed and drinking water ad libitum. K2 (Positive control group) Wistar rats received standard feed, drinking water ad libitum, and 80 mg/kgBW subcutaneous gentamicin injection once for eight consecutive days. P1 (Treatment group 1) Wistar rats received standard feed, ad libitum drinking water, 200 mg/head of purple sweet potato ethanol extract given through a gastric tube, and 80 mg/kg BW of gentamicin injection subcutaneously once for 8 consecutive days. P2 (Treatment group 2) Wistar rats received standard feed, ad libitum drinking water, 400 mg/head of

purple sweet potato ethanol extract given through a gastric tube, and 80 mg/kg BW of gentamicin injection subcutaneously once for eight consecutive days.

On the 9th day, the rats were euthanized using CO<sub>2</sub> inhalation with an optimal flow rate of 30%-70%, following the American Veterinary Medical Association guidelines for harvesting rat liver organs.<sup>12</sup>

Liver tissue preparations that had been made using Hematoxylin and Eosin (HE) staining were observed under a light microscope with a magnification of 400 times. Each preparation was randomly observed in 5 different fields of view, which were considered to represent the overall picture. The degree of histopathological damage to the liver of Wistar rats refers to the Manja Roenigk scoring system. Normal cells were given a score of 1 point, cells undergoing parenchymatous degeneration were given a score of 2 points, cells undergoing hydropic degeneration were given a score of 3 points, and necrotic cells were given a score of 4 points.

The resulting data were analyzed statistically using the SPSS 26 program with normality and homogeneity tests. The data obtained were normally distributed and homogeneous, then continued with the One Way Anova test to compare one group with another group and continued with the Tukey

Post Hoc Test to find out which group was most significant in reducing the incidence of liver damage.

This study received ethical permission approved by the Research Ethics Commission of the Faculty of Medicine, Universitas Jenderal Achmad Yani, on 1 July 2024, number 010 / UH1.07 / 2024.

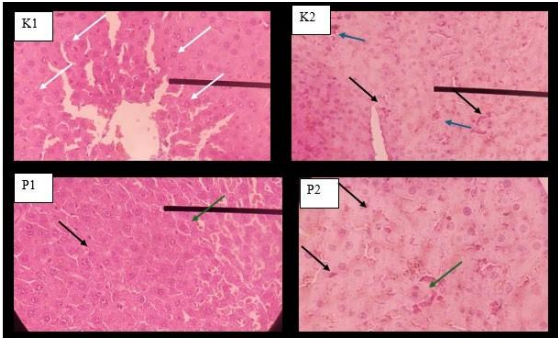
## RESULT

### Qualitative Histological Observation

Microscopic observation obtained different results from each treatment group. Figure 1 (K1) is a histopathological picture of the negative control group, showing a histological picture with the most hepatocyte cells being normal. In some fields of view, there are hepatocyte cells with parenchymatous degeneration in minimal numbers. In general, each preparation has a picture of hepatocyte cells undergoing necrosis, which is normal and not pathological. Pathological events occur when there is increased damage and necrosis of hepatocyte cells.<sup>13</sup>

Figure 1 (K2) is a positive control group with gentamicin induction of 80mg/kgBW/day subcutaneously for 8 days. The histological picture shows that there are still many normal hepatocyte cells. Still, there is an increase in the number of hepatocyte cells with parenchymatous and

hydropic degeneration and necrosis. This condition shows that Group K2 has more severe damage than Group K1. Group K2 has the highest degree of liver cell damage compared to other groups. Figure 1 (P1) is a group given orally 200mg/head/day of purple sweet potato ethanol extract and 80mg/kg BW/day of gentamicin subcutaneously for 8 days. In the histological picture, there were more normal hepatocyte cells compared to the positive control group K2. Hepatocyte cells with parenchymatous degeneration, hydropic, and necrosis can also be found in group P1, but the number is less than in the positive control group K2. Figure 1 (P2) is a group given orally 400mg/head/day of purple sweet potato ethanol extract and 80mg/kg BW/day of gentamicin subcutaneously for 8 days. In the histological picture, there were more hepatocyte cells with parenchymatous degeneration, hydropic degeneration, and necrosis compared to group P1, but not more than group K2.



**Figure 1.** Microscopic images of groups K1, K2, P1, and P2 show normal liver cells (white arrows), parenchymal degeneration (blue arrows), hydropic degeneration (green arrows), and necrosis (black arrows).

### Quantitative Histological Observation

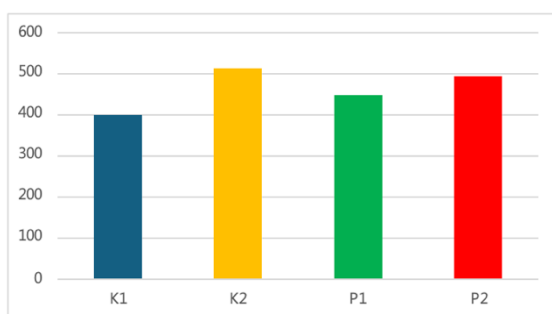
Measurement of histological damage to hepatocyte cells using Manja Roenigk scoring. The average results of Manja Roenigk's scoring in each group can be seen in Table 1 and Graph 1.

The table and graph show Manja Roenigk's scoring average for each group. The average value of Manja Roenigk's scoring explains the degree of hepatocyte cell damage in each group. The higher the average score, the higher the degree of hepatocyte cell damage. The lowest average value was in Group K1 (negative control), followed by Group P1 (200mg/head purple sweet potato ethanol extract with 80mg/kgBW gentamicin induction) and Group P2 (400mg/head purple sweet potato ethanol extract with 80mg/kgBW gentamicin induction). The group with the highest average value was Group K2

(positive control 80mg/kgBW gentamicin induction).

**Table 1.** Average Scoring of Roenigk's Manja

Group	n	Mean of Roenigk's Manja
K1	3	399
K2	3	512
P1	3	447.66
P2	3	492.66



**Figure 2.** Average Scoring Chart of Manja Roenigk.

The Manja Roenigk scoring data from all histological preparations, calculated manually, were then entered into SPSS version 26.00 to be tested statistically (data attached). First, the Manja Roenigk score data were tested for normality using the Shapiro-Wilk. The Shapiro-Wilk test was used because the number of samples in this study was less than fifty.

In the Shapiro-Wilk test, a p-value of 0.903 ( $p > 0.05$ ) was obtained, so it can be concluded that the data distribution in this study was normal (data attached).<sup>14</sup>

Furthermore, a homogeneity test of variance was carried out, and a p-value of 0.668 ( $p > 0.05$ ) was obtained, so it can be concluded that the distribution of the data

from this study has the same variance (data attached). A one-way ANOVA test can be carried out because the test results obtained a normal data distribution and the same variance.<sup>14</sup>

**Table 2.** Effect of ethanol extract of purple sweet potato (*Ipomoea Batatas L.*) on the liver of Wistar rats exposed to gentamicin based on histopathological images

Group	N	Mean± SD	P-value
K1	3	399	0.013*
K2	3	512	
P1	3	447.66	
P2	3	492.66	

ANOVA test, \* $p < 0.05$  significant

In the one-way ANOVA test, the p-value was obtained = 0.013 ( $p < 0.05$ ), which indicates

The results of the one-way ANOVA test can be seen in Table 2, which obtained a p-value = 0.013 ( $p < 0.05$ ), which indicates a significant difference between the average scores of the Manja Roenigk scores between groups. Thus, the Post Hoc test was continued to determine which group had a significant difference. Post Hoc analysis is a further analysis after one-way ANOVA to see if there is a more specific difference between administering different extract doses to the liver of rats induced by gentamicin.<sup>14</sup>

Referring to the one-way ANOVA test criteria, if the p-value  $< 0.05$ , there is a significant difference in the group. So, it can



be concluded that group K1 (negative control) with group K2 (positive control) and group P2 (400mg purple sweet potato extract with gentamicin) with group K1 (negative control) have a significant difference, which means that gentamicin can damage liver cells and ethanol extract of purple sweet potatoes that is too high can damage liver cells instead of being a hepatoprotector. In group P1 (200mg purple sweet potato extract with gentamicin), there was no significant difference with group K1 (negative control), meaning that purple sweet potato extract in the correct dose can function as a hepatoprotector. However, when group P1 was compared with group K2 (positive control), it still did not reach the expected value ( $p<0.05$ ).

**Table 3.** Specific difference between administering different extract doses to the liver of rats induced by gentamicin

Group test	Compared Group	p-value
K1	K2	0.013 (*)
	P1	0.338
	P2	0.034 (*)
K2	K1	0.013 (*)
	P1	0.157
	P2	0.888
P1	K1	0.338
	K2	0.157
	P2	0.397
	K1	0.034 (*)
	K2	0.888

P2	P1	0.397
----	----	-------

Post hoc Tukey (HSD) test, \* $p < 0.05$  significant

## DISCUSSION

### Hepatocyte Cell Damage

The difference in the degree of damage in groups K1 and K2 indicates that gentamicin has a hepatotoxic effect. It follows previous studies that gentamicin at a dose of 80 mg/kgBW can damage the liver histopathologically.<sup>9</sup> The mechanism of hepatocyte cell damage is caused by ischemia. Gentamicin will form free radicals and increase ROS, which disrupts oxygen supply, resulting in ischemia. Decreased oxygen causes decreased production of ATP (adenosine triphosphate), which disrupts cell activity.<sup>6</sup> Disruption of this cell activity causes disruption of active transport, where active transport aims to move sodium from intracellular to extracellular, which causes accumulation of intracellular fluid. Cell organelles can then experience swelling and damage, including the endoplasmic reticulum and mitochondria. This mitochondrial damage causes cytochrome c to release, which binds to apoptotic protease-activating factor 1 (apaaf-1). This bond will activate the process of liver cell apoptosis, resulting in necrosis.<sup>15</sup>

The decrease in damage in group P1 was caused by purple sweet potato extract

containing anthocyanins as an antioxidant. Anthocyanin is a flavonoid compound that can act as an antioxidant. Anthocyanin has a conjugated double bond arrangement in its structure that functions as a natural, free radical destroyer and scavenger. Anthocyanins can counteract various types of reactive oxygen derivative free radicals, such as hydroxyl (OH), peroxy (ROO), and singlet oxygen (O<sub>2</sub>).<sup>16</sup>

The increase in the degree of damage in the P2 group is thought to be caused by the dose of purple sweet potato extract that is too high. Purple sweet potatoes contain components, including polyphenols. Polyphenols and anthocyanins can be prooxidants in addition to being antioxidants in high concentrations. Polyphenols in high prooxidative concentrations are thought to cause fat peroxidation, cell damage, and apoptosis. One of the mechanisms for this damage is increasing ROS levels.<sup>17</sup> Antioxidants in high doses can disrupt the interaction of normal physiological ROS concentrations in cells, which are necessary for optimal cellular function. 18 The degree of damage in the P2 group was relatively high, and there was no significant difference with the K2 group as a positive control.

## CONCLUSION

Administration of purple sweet potato (*Ipomea batatas lam*) ethanol extract at 200 mg/head orally can protect against liver damage in male Wistar rats induced by gentamicin at a dose of 80 mg/kgBW subcutaneously. Meanwhile, administration of purple sweet potato (*Ipomea batatas lam*) ethanol extract at 400 mg/head orally cannot protect against liver damage in male Wistar rats induced by gentamicin at 80 mg/kg BW subcutaneously.

## CONFLICT OF INTEREST

There is no conflict of interest in this study.

## ACKNOWLEDGEMENT

While working on this manuscript, the author received much help, guidance, and advice from many parties. Therefore, the author would like to thank the Faculty of Medicine, Jenderal Achmad Yani University, the examination team, family, colleagues, and all parties who have helped prepare this research.

## REFERENCES

1. Galaly S.R., Ahmed O.M., Mahmoud A.M., Thymoquinone And Curcumin Prevent Gentamicin- Induced Liver Injury By Attenuating Oxidative Stress, Inflammation And Apoptosis.

- Journal Of Physiology And Pharmacology. 2014;65(7):823–32.
2. Prasetiawan E, Sabri E, Ilyas DS. Gambaran Histologis Hepar Mencit (*Mus Musculus L.*) Strain Ddw Setelah Pemberian Ekstrak N- Heksan Buah Andaliman (*Zanthoxylum Acanthopodium* Dc.) Selama Masa Pra Implantasi Dan Pasca Implantasi.
  3. Miladiyah I. Toksidinamik Antibiotika Golongan Aminoglikosida. JKKI. 2010;2(5). Gan, V.S.H., dan Istiantoro, Y.H., 2007, Peisilin, Sefalosporin dan Antibiotik Betalaktam Lainnya, dalam Gunawan, S.G., Setiabudy, R., Nafrialdi. dan Elysabeth., Farmakologi dan Terapi, Hal 667, 678, 681, Bagian Farmakologi Fakultas Kedokteran Universitas Indonesia, Jakarta.
  4. Dewi R, Normasari R. Efek Proteksi Ekstrak Daun Singkong terhadap Hepatotoksisitas yang Diinduksi Gentamisin pada Mencit.. *Journal of Agromedicine and Medical Sciences*. 2019;5(3):177–82.
  5. Almohawes ZN. Protective Effect of Melatonin on Gentamicin Induced Hepatotoxicity in Rats. *Journal of Pharmacology and Toxicology*. 2017 Jun 15;12(3):129–35.
  6. Hendarto L, Tagor Marsillam Siregar dan, Perikanan dan Ilmu Kelautan dan Jurusan Teknologi Pangan UPH FU. as a Partial Substitute of Wheat flour and Source of Antioxidant on Plain Bread]. Vol.1. 2009.
  7. Jawi IM. Peran Antosianin Ekstrak Umbi Ubijalar Ungu Untuk Memelihara Kesehatan Melalui Khasiat Antioksidan. *Farmakologi FK UNUD*. 2016.
  8. Susianti. Pengaruh Ekstrak Jintan Hitam (*Nigella Sativa* L.) terhadap Gambaran Histopatologi Hepar, Paru, dan Testis Tikus Putih (*Rattus Norvegicus*) yang Diinduksi Gentamisin. *Jurnal Sainsmat*. 2013;2(2):107–18.
  9. Siahaan G.S., Lintong P.M., Loho L.L.. Gambaran histopatologik ginjal tikus wistar (*Rattus norvegicus*) yang diinduksi gentamisin dan diberikan ubi jalar ungu (*Ipomoea batatas* L. Poir). *Jurnal e-Biomedik (eBm)*. 2016;4(1)
  10. Sugiritama IW, Ayu Ika Wahyuniari I, Ayu Dewi Ratnayanti IG, Linawati NM, Nyoman Sri Wiryawan IG, Nyoman Arijana IGK. Ekstrak Etanol Ubi Jalar Ungu (*Ipomea batatas* L.) Menurunkan Kadar MDA Plasma Tikus Model Menopause. *Indonesian Journal of Human Nutrition*. 2022;9(1):49–60.

11. Richmond S. AVMA 2016 slaughter guidelines. *Animal Welfare*. 2017;26(1):121–1.
12. Wardanela M. Studi Histopatologi Pengaruh Pemberian Enterotoksin *Enterobacter sakazakii* pada Mencit (*Mus musculus*) Neonatus. IPB. 2008;
13. Dahlan M. Statistik Untuk Kedokteran Kesehatan. Jakarta: Epidemiologi Indonesia; 2014.
14. Darwin M. The Pathophysiology of Ischemic Injury. Alcor Live Extension Foundation: 1995;
15. Priska M, Peni N, Carvallo L, Dala Ngapa Y. Review: Antosianin Dan Pemanfaatannya. Vol. 6, *Cakra Kimia (Indonesian E- Journal of Applied Chemistry)*. 2018.
16. León-González AJ, Auger C, Schini-Kerth VB. Pro-oxidant activity of polyphenols and its implication on cancer chemoprevention and chemotherapy. *Biochem Pharmacol*. 2015 Dec 1;98(3):371–80.
17. Bouayed J, Bohn T. Exogenous antioxidants - Double-edged swords in cellular redox state: Health beneficial effects at physiologic doses versus deleterious effects at high doses. Vol. 3, *Oxidative Medicine and Cellular Longevity*. 2010. p. 228–37.