

**PERIODONTAL APPROACH TO GINGIVITIS PATIENT WITH FIXED ORTHODONTICS APPLIANCES**  
***(PENDEKATAN PERIODONTAL PADA PASIEN GINGIVITIS DENGAN PERANTI ORTODONTI TETAP)***

Frita Ferlita Shafri Djohan<sup>1\*</sup>

<sup>1</sup>Departement of Periodontology, Faculty of Dentistry, Universitas Jenderal Achmad Yani, Cimahi, Indonesia

\*Corresponding author

[frita.ferlita@lecture.unjani.ac.id](mailto:frita.ferlita@lecture.unjani.ac.id)

Doi:  
10.54052/jhds.v1n3.p289-298

**Article History**  
Received: 01/12/2021  
Accepted: 31/12/2021

**ABSTRACT**

Comprehensive care of a patient from multidisciplinary periodontics and orthodontic is found in gingivitis cases with patients that use fixed orthodontics appliances. Periodontal pathogenic bacteria were initiated to dental plaque formation, followed by predisposing factors such as fixed orthodontic appliance, orthodontic movement, and bad oral hygiene. This case report describes a female patient (23 years old) who needs treatment at the anterior mandibular region. Clinical examination explained crowding anterior 32, 31, 41, 42 and applied bracket on each tooth. Pocket depth on the facial side was average 6-5 mm, accompanied by bleeding on probing. Periodontal approach for gingivitis used gingivectomy and gingivoplasty with blade number 15c to eliminate gingival pocket on crowding teeth at anterior mandibular region. Evaluation results in one week and one month after surgery showed healthy gingiva with an average probing depth of 3mm. Gingivectomy is a periodontal approach for gingivitis in patients with fixed orthodontics appliances that could create healthy gingiva and follow excellent oral hygiene instructions.

**Keywords:** gingivectomy; gingivitis; orthodontic; plaque

## **ABSTRAK**

*Perawatan komprehensif pasien dari multidisiplin periodontik dan ortodontik ditemukan pada kasus gingivitis pasien yang menggunakan alat ortodontik cekat. Bakteri patogen periodontal diawali dengan pembentukan plak gigi, diikuti oleh faktor predisposisi seperti alat ortodontik cekat, pergerakan ortodontik, dan kebersihan mulut yang buruk. Laporan kasus ini menggambarkan seorang pasien wanita (23 tahun) yang membutuhkan perawatan di regio anterior mandibula. Pemeriksaan klinis memperlihatkan crowding anterior 32, 31, 41, 42 dan pemasangan braket pada masing-masing gigi. Kedalaman poket pada sisi fasial rerata 6-5 mm, disertai perdarahan saat probing. Pendekatan periodontal untuk gingivitis menggunakan gingivektomi dan gingivoplasti dengan blade number 15c untuk menghilangkan poket gingiva pada gigi yang berjejal di regio mandibula anterior. Hasil evaluasi satu minggu dan satu bulan setelah operasi menunjukkan gingiva sehat dengan kedalaman probing rata-rata 3mm. Gingivektomi merupakan pendekatan periodontal untuk gingivitis pada pasien dengan peralatan ortodontik cekat yang dapat menciptakan gingiva yang sehat dan mengikuti instruksi kebersihan mulut yang baik.*

**Kata kunci:** *gingivektomi; gingivitis; ortodontik; plak*

## **INTRODUCTION**

A pathological condition that happened in an intraoral patient was multifarious. Based on the chief complaint, the vital thing is the choices consideration of therapy. Disease severity was a base point to make a treatment plan. However, if there is much severity, it can be considered to do multidiscipline sustainable therapy in one moment. It is called comprehensive care patient, multidisciplinary therapy

concept which careful consideration become a proper treatment plan.<sup>1</sup>

The example from comprehensive care patient work was a collaboration between a periodontist and orthodontist. Patients with fixed orthodontics treatment could have a side effect on periodontal tissue—factors where prompt emerging periodontal tissue alteration could be judged carefully. Plaque formation is the initial process from pathologic condition

and will develop to advance periodontal disease when be ignored.

The retentive area in intra oral is suitable for a dental plaque for living. These areas are supra gingival calculus, sub gingiva, cemento-enamel junction, furcation and its irregular form, fissure and groove, cervical surface and root caries, and crowding teeth. Besides, there are iatrogenic predisposing factors and dentistry restoration or treatment materials used for a long time.<sup>2</sup> Related to fixed orthodontics appliance, the materials applied to intra oral tended to create plaque retention areas. For example, are bracket, wire, buccal tube, elastic rubber, band, and many more. Once again, that condition could be worse if the patient has bad oral hygiene, plaque formation could be grown faster and precipitate advanced periodontal disease.

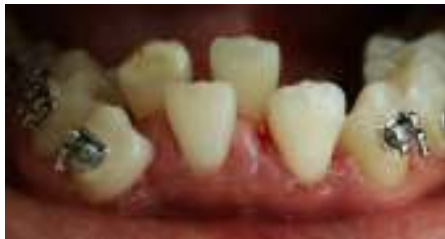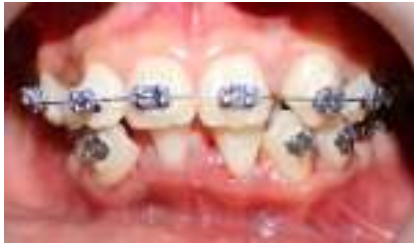Gingivitis is known as marginal gingiva inflammation due to periodontal pathogenic bacteria formed in dental plaque.<sup>3</sup> Etiology from gingivitis not only one reason but multifactorial. Pathogenic bacteria were the initial factor that made an inflammation. Local factors trigger gingivitis from ortho-perio correlation is considered from movement such as fixed orthodontics appliances, bad oral hygiene, and gingiva fibers response as compensation lead enlargement gingiva,

and another condition that could worsen.

Gingivitis in fixed orthodontics patients who didn't soon treat could inhibit successful orthodontics treatment. Because of that, comprehensive therapy from a periodontist for this case eliminates the inflammation or gingival pocket. Gingivectomy and gingivoplasty be considered after the initial treatment to restore normal morphology and healthy gingiva.

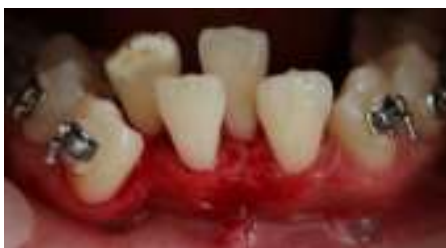## CASE REPORT

A female patient (23 years old) came to a periodontist based on reference from an orthodontist for periodontal treatment at the anterior mandibular region. Clinical examination explained crowding anterior 32, 31, 41, 42 and applied bracket on each tooth. Marginal gingiva found oedema on the facial side. Pocket depth on the facial side was average 6-5 mm, accompanied by bleeding on probing. The initial phase in treatment between scaling, one week and one-month recall visits was done. In one month visit after scaling, pocket depth got average of 4-5 mm on facial side 32, 31, 41, 42 (Figure 1A and 1B).



**Figure 1.** (A) First condition gingival oedema at facial region 32, 31, 41, 42. (B) First condition gingival oedema at facial region 32, 31, 41, 42 when mouth open.

Gingivectomy was planned after evaluation from the initial phase. Initiated with oral prophylaxis, bleeding points made on the pocket marker area can be reached under anesthesia. Excision with Castroviejo scissor and blade number 15c elected because the inflammation gingiva was narrow, so small sharp beak instruments needed to reach this area. Tampon soaked with aquabidest applied to bleeding gingiva to get clear surgery area (Figure 2).

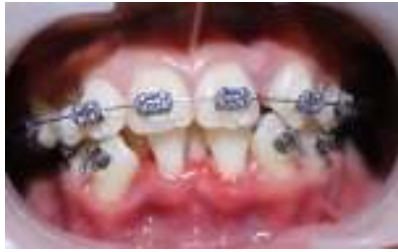

**Figure 2.** Gingiva facial side teeth 32, 31, 41, 42 after gingivectomy.

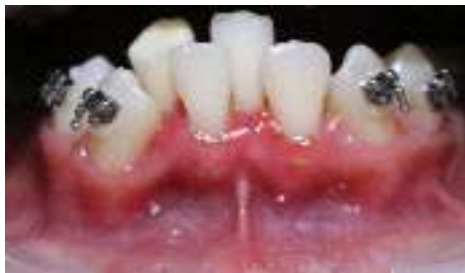Re-probing to make sure sulcus depth was not interrupted biological width. The next step is to scale on teeth 32, 31, 41, 42 with a manual scaler to eliminate residual plaque that attaches to the enamel surface after excision.

Excision procedure left lapsed angle at the facial side in healthy gingiva, until need adjustment to create normal morphology. Gingivoplasty had done by high speed with the flame from a fine bur instrument. Debridement with NaCl and the precise area must be sure after the periodontal pack covers that surgery area. The patient has been given education oral hygiene instruction after gingivectomy procedures.

Evaluation in one week after gingivectomy explained had not found complaints from the patient and periodontal pack still covered 32, 31, 41, 42 facial regions. Periodontal pack eliminated and followed by spooling NaCl. Clinical examination on gingiva facial region 32, 31, 41, 42 still had inflammation at mesial 32, 31, mesial 41, and 42 on margin gingiva (Figure 3). Inflammation area applied gel contained aloe vera and folic acid to accelerate wound healing as adjunctive therapy. The patient has been given education, especially tooth brushing techniques in after surgery area.



3A



3B

**Figure 3.** (3A) Evaluation in one week after gingivectomy procedures, the gingival margin still had inflammation in some areas and occlusion appearance.

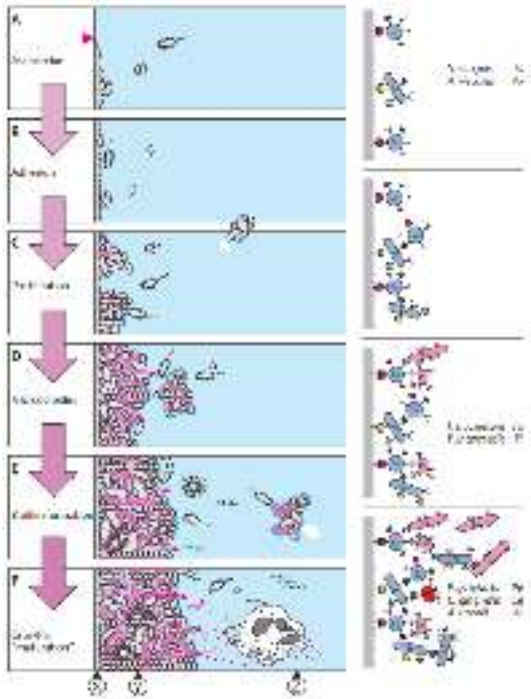
(3B) Evaluation in one week after gingivectomy procedures, the gingival margin still had inflammation in some areas when the mouth was open.

We are probing depth in one week after gingivectomy procedures at facial regions 32, 31, 41, 42 average on 3 mm. After one month, sulcus depth is still the same with a healthy gingival margin appearance. The last periodontal assessment could be considered fixed orthodontics treatment, under monitoring the patient's oral hygiene by periodontist once a month, in the first six months.

## DISCUSSION

Periodontics and Orthodontics case collaboration was found on gingivitis in patients with fixed orthodontics treatment with the example for comprehensive care patients. Orthodontic treatment with a fixed orthodontics appliance has side effects on periodontal tissue. Pathological condition in periodontal tissue starts from plaque formation and will be more destructive when ignored.

Plaque formation started with pellicle adhered all over intra oral surface, including teeth. Pellicle had receptors that could bind to adhesin signal from initial bacteria, commonly found in *Streptococcus sp.* and *Actinomyces sp.*, to build primary colonization. Microcolony was formed with self-protection ability in the proliferation stage by producing extracellular polysaccharides from the *Streptococcus sp.* genus. Micro colonies get more substantial with their metabolism function. In this stage, it's known as a biofilm. Biofilm had "primitive circulation" and a more diverse population; anaerobic microorganism increase produced lipopolysaccharide as host response (PMN) protection (Figure 4).<sup>2</sup> Complex biofilm will mature in 24 hours.



**Figure 4.** Dental plaque development. A. Association, B. Adhesion, C. Proliferation, D. Microcolonies, E. Biofilm, F. Plaque maturation.<sup>2</sup>

Gingivitis happened by multifactorial etiology. Dental plaque is the initial etiology generated by periodontal pathogenic bacteria. While risk factors also influence, in this case from iatrogenic factors, fixed orthodontics appliances 4, among others bracket 5, 6, wire, buccal tube, elastic rubber, band, and orthodontics movement could impact periodontal tissue.<sup>4</sup> When a patient in a fixed orthodontics device can't clean their teeth, then plaque accumulation on the widget leads to gingival inflammation.<sup>6</sup>

Fixed orthodontics appliances create movement did affect elongated gingiva fibers from marginal to attached gingiva as compensation from tooth movement.

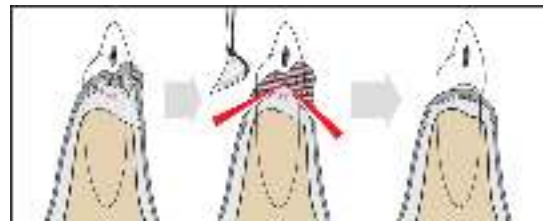
Generate to enlargement and gingival pocket.<sup>7,8</sup> And aggravated with bad oral hygiene, the plaque grew faster, and the effects advanced periodontal breakdown. Intrusion and tipping could bring supragingival plaque going apically to the subgingival sulcus.<sup>4</sup> Orthodontics contribute as local factors found in crowding teeth, teeth configuration not aligned in jaw arch lead inter proximal hard to clean.<sup>9</sup> Malposition teeth have a chance of plaque retention and food impaction.<sup>10</sup>

The force from orthodontics movement to teeth affected periodontal tissue alteration can explain histologically. The gentle movement associated with compression side made periodontal ligament pushed but still vital, bone resorption occurs by osteoclasts activity and at tension side bone apposition occurs by osteoblasts activity.<sup>11</sup> However, the heavy movement made the periodontal ligament at the force side broken, hemorrhage, thrombosis, and necrosis. Neither bone resorption due to periodontal ligament nutrient supply inadequate affected tooth movement inhibition.<sup>10</sup> Besides high value from index plaque and no evaluation, it also creates periodontal inflammation.

Gingivitis is periodontal soft tissue inflammation that occurs in the gingival margin due to periodontal pathogenic bacteria formed in dental plaque.<sup>3</sup> Gingival

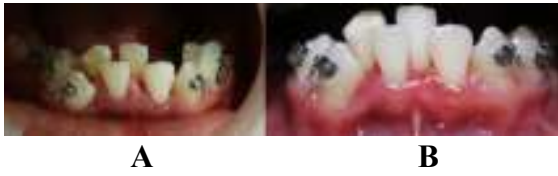pocket had treated in initial periodontal therapy through active inflammation. The next plan is gingivectomy when the probing depth is over 3 mm. Gingivectomy is a soft tissue resection treatment to eliminate plaque retentive zone, impacting infection, especially pocket. External bevel incision can also use electro surgery or laser to eliminate gingival pocket with a blade.<sup>7,12</sup> Before excision, pocket pattern marks with bleeding point use pocket marker applied at pocket base. External bevel incision started put blade apically from the bleeding point with bevel 45° to root surface, blade direct to crown.<sup>7</sup>

Indications from gingivectomy are supra bony pocket, have no furcation involvement defects, enlargement gingival effects from systemic conditions, medications, or margin and contour created from fixed restoration needs. Excision ended cannot exceed cemento enamel junction. It was followed by gingivoplasty to reform the gingival surface cut using a blade (Figure 5), diamond bur and high speed, electro surgery, or laser.<sup>7</sup> Followed by scaling with instruments worked at the crown and root surfaces area to remove plaque, stains, or calculus.<sup>13</sup> With pocket depth in medium criteria (4-6 mm), manual scaler was statically significant for effectiveness than ultrasonic scaler to pocket depth reduction.<sup>14</sup>



**Figure 5.** Gingivectomy or gingivoplasty. Left: the case of enlargement gingiva in periodontitis, Middle: pocket removed and sculpted by gingivoplasty. Right: Healthy gingiva after surgery.<sup>12</sup>

Gingivectomy performed on regions 32, 31, 41, 42 with the blade had the optimal result. Until one-month post-surgery evaluation, there was no indication of gingivitis recurrent with a probing depth average of 3 mm (Figure 6). Wound healing response commonly involves three phases: blood coagulation and inflammation, nascent tissue formation, and tissue remodeling. Blood coagulation is activated to control local bleeding. During 2-10 days after surgery, new tissue formation involved migrations and proliferations connective tissue, epithelial, and endothelial cells to build outer defensive surface from pathogenic bacteria during the healing process. The duration of the remodeling phase depends on risk factors, especially lesion size. This phase starts two weeks after surgery and probably could be for one year or more.<sup>15</sup>



**Figure 6.** Gingival margin facial region  
32, 31, 41, 42

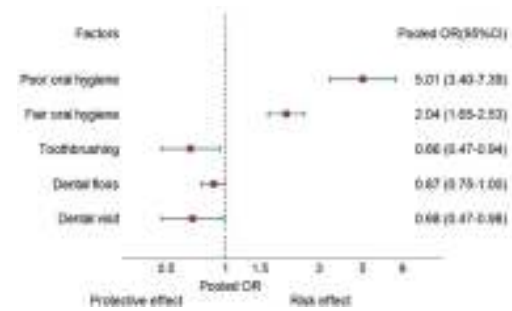
(A) Before gingivectomy procedures, (B) After gingivectomy procedures.

A patient recall visits once a month was recommended to evaluate plaque index and oral hygiene education. Dentist visits and tooth brushing appropriately, as expert-recommended could reduce periodontitis by 34% and 32%, respectively (Table 1 and Figure 6).<sup>16</sup>

**Table 1.** Overview of the meta-analysis

Risk factor	No. of studies	Pooled OR (95% CI)	I <sup>2</sup> (P%)	Quality of evidence <sup>a</sup>
<b>OH</b>				
Categorical data				
Fair OH versus Good OH	9	2.04 (1.65–2.55)	49	Moderate
Poor OH versus Good OH	12	5.01 (3.49–7.09)	78	
Continuous data				
PI: 1-unit increase	6	2.35 (1.43–3.94)	81.1	
PS: 1-unit increase	3	1.02 (1.01–1.05)	74.2	
OHI score	25	2.04 (1.59–2.60) <sup>b</sup>	95.6	
Oral health-care habits				
Toothbrushing	10	0.66 (0.47–0.94)	94.5	Very low
Interdental cleaning	4	0.87 (0.75–1.00)	5.1	Low
Dental visits	6	0.88 (0.47–0.98)	60.4	Very low

OHI, oral hygiene; PI, plaque index; PS, plaque score.  
<sup>a</sup>Quality of evidence: The Grades of Recommendation, Assessment, Development and Evaluation Working Group (GRADE Working Group).  
<sup>b</sup>Pooled standard mean difference (SMD).



**Figure 7.** Summary of pooled effect of oral hygiene (OH) and oral care habits on periodontitis. OR, odds ratio.<sup>16</sup>

## CONCLUSION

Gingivitis therapy in a patient with fixed orthodontics treatment was a multidisciplinary comprehensive collaboration in dentistry-gingivectomy as a treatment plan to eliminate gingival pocket in this case, after the initial phase. Periodontal pathogenic bacteria were initially etiology from dental plaque formation, besides predisposing factors in its local intra oral can also determine to occur periodontal disease. High-value plaque index unevaluated bad oral hygiene had a significant role in periodontal tissue destruction. Gingivitis, especially with crowding teeth, is a challenge for the operator to choose the right surgery instrument and convenience handling to eliminate gingival pockets. Post-surgery evaluation accompanied by home care education is the following plan to keep from recurrent gingivitis.



## CONFLICT OF INTEREST

The author declares no conflict of interest. This case reports no external funding or support from the author's institution.

## ACKNOWLEDGEMENT

Author's gratitude to the professional orthodontist in the dental clinic who allowed shares this multidisciplinary case and the involved author did periodontal therapy for this patient.

## REFERENCES

1. Rateitschak K, Wolf H, Hassel T. Data collection-diagnosis-prognosis. In: Color atlas of dental medicine periodontology. 3rd ed. Stuttgart: Thiem; 2011: 165.
2. Rateitschak K, Wolf H, Hassel T. Biofilm-plaque formation on tooth and root surface. In: Color atlas of dental medicine periodontology. 3rd ed. Stuttgart: Thiem; 2011: 24–6.
3. Rateitschak K, Wolf H, Hassel T. Gingivitis. In: Color atlas of dental medicine periodontology. 3rd ed. Stuttgart: Thiem; 2011: 79.
4. Guo R, Lin Y, Zheng Y, Li W. The microbial changes in subgingival plaques of orthodontic patients: A systematic review and meta-analysis of clinical trials. BMC Oral Health. 2017; 17(1): 1–10.
5. Lee SM, Yoo SY, Kim H-S, Kim K-W, Yoon Y-J, Lim S-H, et al. Prevalence of putative periodontopathogens in subgingival dental plaques from gingivitis lesions in Korean orthodontic patients. J Microbiol [Internet]. 2005 Jun; 43(3): 260–5. Available from: <http://www.ncbi.nlm.nih.gov/pubmed/15995644>
6. Atassi F, Awartani F. Oral hygiene status among orthodontic patients. J Contemp Dent Pract. 2010; 11(4): 25–32.
7. Serio F, Hawley CE. Manual of clinical periodontics. 4th ed. Hudson: Lexi-Comp; 2014: 83,84.
8. Hinrichs J, Thumbigere-Math V. The role of dental calculus and another predisposing factor. In: Newman M, Takei H, FACHD, Carranza F, editors. Newman and Carranza's clinical periodontology. 13th ed. Philadelphia: Saunders; 2017: 1189–262.
9. Greenwell H. Local contributing factors. In: Periodontics: Medicine, surgery, and implants. St. Louis: Mosby; 2004: 126.
10. Cohen D, Goldman H. Periodontal Therapy. 5th ed. St. Louis: Mosby; 1973: 208.
11. Jiang N, Guo W, Chen M, Zheng Y, Zhou J, Kim SG, et al. Adaptation: tooth movement. Front Oral Biol. 2016; 18: 1-8.
12. Rateitschak K, Wolf H, Hassel T.

- Phase 2 therapy periodontal surgery-corrective phase. In: *Color atlas of dental medicine Periodontology*. 3rd ed. Stuttgart: Thieme; 2011: 295-9.
13. Profili F, Sparabombe S, Tawse Smith A, D’Isidoro O, Quaranta A. The effect of miniaturized manual versus mechanical instruments on calculus removal and root surface characteristics: An in vitro light microscopic study. *Clin Exp Dent Res* [Internet]. 2019 Oct 15; 5(5): 519–27. Available from: <https://onlinelibrary.wiley.com/doi/10.1002/cre2.218>
  14. Zhang X, Hu Z, Zhu X, Li W, Chen J. Treating periodontitis-a systematic review and meta-analysis comparing ultrasonic and manual subgingival scaling at different probing pocket depths. *BMC Oral Health*. 2020; 20(1): 176.
  15. Smith PC, Martínez C, Martínez J, McCulloch CA. Role of Fibroblast Populations in Periodontal Wound Healing and Tissue Remodeling. *Front Physiol* [Internet]. 2019 Apr 24; 10(April): 270. Available from: <https://www.frontiersin.org/article/10.3389/fphys.2019.00270/full>
  16. Lertpimonchai A, Rattanasiri S, Arj-Ong Vallibhakara S, Attia J, Thakkinstian A. The association between oral hygiene and periodontitis: a systematic review and meta-analysis. *Int Dent J*. 2017; 67(6):