

MENTAL FORAMEN POSITION ON PANORAMIC RADIOGRAPHS OF PATIENTS AGED 20-44 YEARS BASED ON GENDER AT RSGM UNJANI

(POSISI FORAMEN MENTAL PADA RADIOGRAF PANORAMIK PASIEN USIA 20-44 TAHUN BERDASARKAN JENIS KELAMIN DI RSGM UNJANI)

Mutiara Sukma Suntana^{1*}, Tichvy Tammama², Nabilla Mulya Kurniawan³

¹Department of Dental Radiology, Faculty of Dentistry, Universitas Jenderal Achmad Yani, Cimahi, Indonesia

²Department of Oral and Maxillofacial Surgery, Faculty of Dentistry, Universitas Jenderal Achmad Yani, Cimahi, Indonesia

³Faculty of Dentistry, Universitas Jenderal Achmad Yani, Cimahi, Indonesia

*Corresponding author

mutiara.sukma@lecture.unjani.ac.id

JHDS.unjani.ac.id/jite
Doi: 10.54052/jhds.

Article History
Received: 20/07/2023
Accepted: 10/08/2023

ABSTRACT

The mental foramen is a small hole located in the body of the mandible in the premolar to molar region. There are veins, arteries, and a branch of the inferior nervus alveolaris, the nervus mentalis. The blood vessels and nerves in the mental foramen supply and innervate the lower lip region, gingiva, soft tissues of the chin, and lower teeth. Various factors influence the development of the mental foramen, such as race, age, gender, and ethnicity. Determination of the position of the mental foramen can help in diagnosis, treatment, and some clinical measures related to the mental foramen. This study aims to determine the difference in the position of the mental foramen according to gender and the difference in the position of the right and left mental foramen according to gender in patients at RSGM Unjani. This study was

conducted using an analytical method with a cross-sectional approach. The research object was 44 panoramic radiographs taken with a purposive sampling technique. To analyze the difference in the position of the mental foramen according to gender, the study used the Mann-Whitney test, while to analyze the difference in the right and left positions according to gender; we used the Chi-Square test. The results showed no significant difference in the position of the mental foramen towards gender ($p>0.05$). There was no significant difference in the position of the mental foramen between the left and right on the panoramic radiograph of the patient according to gender ($p>0.05$). The most common position was in line with the lower second premolar with a percentage of 62.5%, and the position of the mental foramen was symmetrical both left and right with a percentage of 52.3%. It can be concluded that there is no significant difference between the position of the mental foramen and gender on panoramic radiographs of patients aged 20–44 years at RSGM Unjani in 2021.

Keywords: growth; mandible; mental foramen; panoramic radiograph

ABSTRAK

Foramen mental adalah lubang kecil terletak pada korpus mandibula di daerah regio premolar hingga molar. Terdapat vena, arteri, dan juga cabang dari nervus alveolaris inferior yaitu nervus mentalis. Pembuluh darah dan saraf pada foramen mental menyuplai dan menginervasi daerah bibir bawah, gingiva, jaringan lunak dagu, dan gigi bawah. Ada berbagai faktor yang mempengaruhi perkembangan foramen mental, seperti ras, usia, jenis kelamin, suku bangsa. Penentuan posisi foramen mental dapat membantu dalam diagnosis, perawatan, dan beberapa tindakan klinis yang berhubungan dengan foramen mental. Penelitian ini bertujuan untuk mengetahui perbedaan posisi foramen mental terhadap jenis kelamin, dan perbedaan posisi foramen mental kanan dan kiri terhadap jenis kelamin pada pasien di RSGM Unjani. Penelitian ini dilakukan menggunakan metode analitik, dengan

pendekatan cross-sectional. Objek penelitian sebanyak 44 radiograf panoramik dengan teknik pengambilan purposive sampling. Untuk analisis perbedaan posisi foramen mental terhadap jenis kelamin dilakukan analisis menggunakan uji Mann-Whitney, sedangkan perbedaan posisi kanan dan kiri terhadap jenis kelamin menggunakan uji Chi-Square. Hasil penelitian menunjukkan bahwa tidak terdapat perbedaan signifikan antara posisi foramen mental terhadap jenis kelamin ($p>0.05$) dan tidak terdapat perbedaan signifikan pada posisi foramen mental antara kiri dan kanan pada radiograf panoramik pasien terhadap jenis kelamin ($p>0.05$). Posisi terbanyak segaris premolar kedua bawah dengan presentase 62.5% dan posisi foramen mental simetris baik kiri maupun kanan dengan presentase 52.3%. Dapat disimpulkan bahwa tidak terdapat perbedaan signifikan antara posisi foramen mental dengan jenis kelamin pada radiograf panoramik pasien usia 20-44 tahun di RSGM Unjani pada tahun 2021.

Kata kunci: *foramen mental; mandibula; pertumbuhan; radiografi panoramik*

INTRODUCTION

The mental foramen is a small hole in the mandible, round or oval in shape, located on the corpus mandible premolar to molar region. The mental foramen contains veins, arteries, and a branch of the inferior nervus alveolaris, the nervus mentalis. The blood vessels and nerves in the mental foramen supply and innervate the lower lip, gingiva, soft tissues of the chin, and lower teeth.^{1-3,15}

Various factors influence the

development of the mental foramen, such as race, age, gender, and ethnicity.^{2,12} The position of the mental foramen in each individual varies, but in general, the mental foramen's position is below the lower jaw's second premolar. As age changes, the position of the mental foramen may also change. In children's teeth that have not erupted, it is usually located close to the alveolar ridge. Still, when it erupts, the mental foramen begins to descend between the upper and lower borders. When the

permanent teeth erupt, especially in adulthood, the mental foramen move inferiorly. In older people or parents who have experienced bone resorption due to tooth loss, the position of the mental foramen will move towards the alveolar ridge.^{1,3,4,26}

Determining the position of the mental foramen can help in diagnosis, treatment, and some clinical actions related to the mental foramen, such as when administering local anaesthesia to the inferior alveolaris nerve, orthognathic surgery, root canal treatment, and dental implants. If there is a failure to determine the location of the mental foramen, it can cause paresthesia in the surgical area or ineffective extraction. Knowing the position of the mental foramen indirectly determines the success of treatment.^{1,3,5,6,14–21}

Based on research by Thakare, et al. (2016) conducted on the population of Pune, central India, with a sample of 100 men and 100 women who had the results of 48% in men and 52% in women, the position of the mental foramen was located in line with the second premolar. The study concluded that there was no difference in the distribution of the position of the mental foramen based on gender.⁷ In addition, research by Chkoura et al. (2013) showed that the position of the mental foramen in

the Moroccan population was not affected by gender.⁸

Based on research by Anshuman et al. (2013), the location of the mental foramen is divided into six criteria; namely, position one is located anterior to the lower first premolar, position two is located in line with the lower first premolar, position three is located between the lower first premolar and second premolar, position 4 is located in line with the lower second premolar, position 5 is located between the second premolar and the mesiobuccal root of the lower first molar, position 6 is located in line with the mesiobuccal root of the lower first molar.^{1,3,27} It was found that the location of the mental foramen was symmetrical both left and right with a percentage of 62.8%, and most were located between the first and second premolars with a total of 46.1%. In comparison, those situated in line with the second premolar were 45.5%.⁹ In research by Fadhillah et al. (2018) regarding age differences in the position of the mental foramen at RSGM TNI AL Yos Sudarso showed that there are three age groupings based on WHO, namely adolescence (10-19 years), adulthood (20-44 years), middle age (45-59 years). However, after analysis, no significant difference was found between age differences in the location of the mental foramen.³

The position of the mental foramen varies, so it needs to be identified with panoramic radiographs. The growth of the jaw, especially the mandible, is influenced by age and gender. At the age of 12-14 years, growth is increasing and stops on average at 20 years, so the location of the mental foramen is more constant. The growth process in women ends sooner than in men. In elderly patients, are prone to edentulous, so the location of the mental foramen changes, which is closer to the alveolar rim, due to the decrease in alveolar bone.^{4,10,12}

The position of the mental foramen varies, so it needs to be identified with panoramic radiographs. The growth of the jaw, especially the mandible, is influenced by age and gender. It is to see the position of the two mental foramen; panoramic radiographs can be used, two-dimensional images showing the upper jaw, lower jaw, and surrounding anatomical structures in one film taken with extraoral radiographic techniques. Panoramic radiographs have several advantages, such as low radiation dose received by the patient and a reasonably broad picture covering the facial bones and teeth.²²⁻²⁵ Therefore, dentists use panoramic radiographs quite frequently, especially in identifying the mental foramen.^{1,11,12} Radiographically, the mental foramen is radiolucent with a round or oval

shape.³

Based on this background, it was found that there were many variations in the position of the mental foramen, so the author wanted to conduct further research on variations in the role of the mental foramen on panoramic radiographs of male and female patients at RSGM Unjani.

METHOD

Research design

This study was conducted using an analytic method, with a cross-sectional approach on panoramic radiographs with the variables to be studied, both independent and dependent variables, measured and observed simultaneously.

Research subject

The object of this study was panoramic radiographs in 2021 at RSGM Unjani Cimahi City, with as many as 44 samples with a purposive sampling technique. The sample inclusion criteria in the study were panoramic radiographs in patients aged 20-44 years at RSGM Unjani, panoramic radiographs with diagnostically acceptable quality, mental foramen on panoramic radiographs can be identified on both sides, panoramic radiographs of patients with complete teeth from the first premolar to the first molar of the lower jaw. Meanwhile, the sample inclusion criteria in

the study were being treated orthodontically, and orthognathic surgery had been performed, mandible in a state of benign or malignant pathology, such as cysts, tumours, or congenital anomalies, panoramic radiographs with mandibular fracture abnormalities, premolars with periapical abnormalities.

Tools and materials

The tools and materials used for this research are viewer, panoramic photo, pencil, pen, eraser, ruler, and HVS paper.

Research procedure

Researchers determine the number of research samples and survey the panoramic photo samples available at RSGM Unjani. Then, the researcher made a research ethics letter and submitted a research permit at RSGM Unjani—sample collection by selecting panoramic radiograph photos that match the sample criteria. Intraobserver training is research conducted by two people with equal perception and trained by competent dentists and observations made by researchers who have attended the training. Observing the position of the mental foramen using a ruler and recording the location of the mental foramen based on Anshuman's criteria (2013), specifically:
Position 1: Anterior to the lower first

premolar

Position 2: In line with the lower first premolar

Position 3: Between the first premolar and the lower second premolar

Position 4: In line with the lower second premolar

Position 5: Between the second premolar and the mesiobuccal root of the lower first molar

Position 6: In line with the mesiobuccal root of the lower first molar.

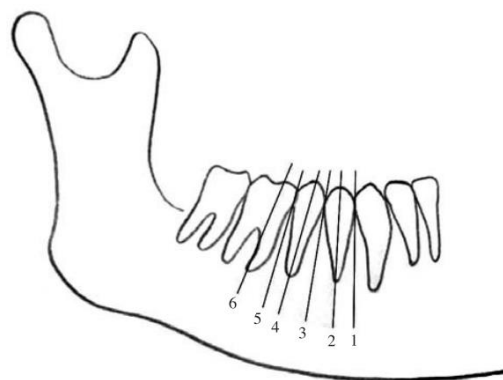


Figure 1. Anshuman criteria (2013) position of the mental foramen.
Quoted from: Chkoura et al.⁸

Then, the observation results were entered into a table. Then, the data was processed and analyzed.

Data analysis

Data analysis to determine the position of the mental foramen on panoramic radiographs of patients aged 20-44 years at RSGM Unjani using the SPSS

software application with the Mann-Whitney and Chi-square tests, which have a p-value <0.05, so there is a significant difference.

Research ethical aspect

The researcher submitted a permission letter and research ethics eligibility letter from the Padjajaran University Research Ethics Committee to protect the medical record data of panoramic radiograph photos in patients aged 20-44 years at RSGM Unjani in this study with number 1056/UN6.KEP/EC/2022.

Place and time of research

The time used by researchers to conduct research was from October to December 2022 and took place in the Radiology Section of the Unjani Dental and Oral Hospital (RSGM), Jl. Encep Kartawiria No.88, Citeureup, North Cimahi, Cimahi City, West Java 40512.

RESULT

The object of this study was obtained from all medical records of panoramic radiographs of RSGM Unjani in 2021, which met the inclusion and exclusion criteria. The distribution of the characteristics of the object of this study is shown in Table 1 as follows.

Table 1. Distribution of research object characteristics based on gender and age.

Characteristics	n(%)
Gender	
Male	20(45.5)
Female	24(54.5)
Age	
20-44 years old	44(100)

This table shows that in the research data, 20 men, a percentage of 45.5%, while 24 women and a percentage of 54.5% were obtained. In this research data, the age of 20-44 is only one age group based on WHO grouping, namely the adult group of 20-44 years and has a percentage of 100%.

The following is the distribution of the location of the mental foramen on panoramic radiographs of RSGM Unjani in 2021 that have met the inclusion and exclusion criteria listed in Table 2.

Table 2. Frequency distribution of mental foramen position on panoramic radiographs.

Position	Located		n(%)
	Right	Left	
1	0	0	0
2	0	0	0
3	15	11	26(29.5)
4	24	31	55(62.5)
5	5	2	7(8)
6	0	0	0

Based on Table 2 for the location of the mental foramen on panoramic radiographs at RSGM Unjani in 2021, most of them are in line with the lower second

premolar or criterion 4 with a percentage of 62.5%. It is followed by the location between the first premolar and the lower second premolar or criterion 3, with a percentage of 29.5%, and the least located between the second premolar and the mesiobuccal root of the lower first molar or criterion 5, with a percentage of 8%. While the locations in criteria 1, 2, and 6 are not found in the research data object. All research data results obtained will be

analyzed as a whole to answer the formulation of the problem regarding differences in the mental foramen position between men and women on panoramic radiographs of patients at RSGM Unjani using SPSS. In this study, two data groups were mutually independent and categorical to be analyzed so that a non-parametric statistical test was performed, namely the Mann-Whitney test. The results are listed in Table 3.

Table 3. Differences in the position of the left and right mental foramen on panoramic radiographs by gender.

Mental Foramen Position	Gender				<i>p-value</i>
	Male		Female		
	n(%)	Mean ± SD	n(%)	Mean ± SD	
Right					
1	0		0		
2	0		0		
3	4(26.7)	3.95 ± 0.60	11(73.3)	3.63 ± 0.65	0.084
4	13(54.2)		11(45.8)		
5	3(60)		2(40)		
6	0		0		
Left					
1	0		0		
2	0		0		
3	6(54.5)	3.75 ± 0.48	5(45.5)	3.83 ± 0.51	0.564
4	13(41.9)		18(58.1)		
5	1(50)		1(50)		
6	0		0		

*) *Mann Whitney*, $p < 0.05$

The results showed that the relationship between the position of the right mental foramen on panoramic radiographs based on gender showed no significant difference between men and women because the $p > 0.05$. The

relationship between the position of the left mental foramen on panoramic radiographs based on gender shows no significant difference between men and women because the $p > 0.05$.

The research data obtained is

analyzed using SPSS to answer the problem formulation regarding the difference in the position of the left and right mental foramen on panoramic radiographs of male and female patients at RSGM Unjani. In this study, two data groups were mutually independent and categorical to be analyzed so that a non-parametric statistical test was performed, namely the Chi-Square test.

The following graph shows data on the symmetry of the position of the right and left mental foramen, namely symmetrical and asymmetrical in the position of the right and left mental foramen of the patient's panoramic radiograph based on gender, as shown in Figure 2.

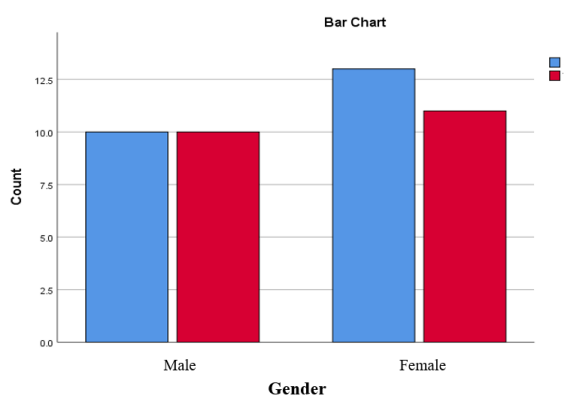


Figure 2. Symmetrical and asymmetrical graphs of the mental foramen position on panoramic radiographs of patients between male and female

The following analysis results on the difference in the position of the left and right mental foramen on panoramic radiographs based on gender are listed in Table 4.

Table 4. Left and right mental foramen positions on panoramic radiographs by gender.

Variable	Symmetry n(%)	Asymmetry n(%)	Total	p-value
Gender				
Male	10(50)	10(50)	20	1.000
Female	13(54.2)	11(45.8)	24	
Total	23(52.3)	21(47.7)	44	

*) Chi-square, $p < 0,05$

Based on the table, shows that the position of the mental foramen is symmetrical both left and right, with a percentage of 52.3%, while those who are not symmetrical get a percentage of 47.7%. However, there is no significant difference between the position of the left and right mental foramen based on gender because the $p > 0.05$.

DISCUSSION

In research conducted at RSGM Unjani, researchers used a purposive sampling technique to take samples that met the inclusion criteria of panoramic radiographs of patients aged 20-44 years. Then, select samples based on specific criteria. After collecting the samples, observations were made with the help of a viewer, and then the data was obtained, processed, and analyzed using SPSS software.

Based on the results of the study, it is known that the position of the mental

foramen based on Anshuman's criteria (2013) in Unjani RSGM patients, the most common position is found to be in line with the lower second premolar or classification 4 with a percentage of 62.5%. Then, followed by the location between the first premolar and the second lower premolar or classification 3 with a percentage of 29.5%, and the least located between the second premolar and the mesiobuccal root of the lower first molar or classification 5 with a percentage of 8%. It follows the research of Manja et al. (2018) in the population of Batak ethnic students at the USU Faculty of Dentistry, and most position is located in line with the lower second premolar, which is 42.1%. However, this is different from the results of Anshuman et al. (2013) in the population of Rajasthan, India, who found that the location of the mental foramen mainly was located between the first and second premolars with a total of 46.1%, while those located in line with the second premolar were 45.5%.⁹

According to most authors, the mental foramen is often located between the first and second premolars or in line with the mandibular second premolar. However, variations in the position of the mental foramen within each individual can occur in different populations, which can be influenced by genes or mandibular growth and development factors in each

individual.⁹ In this study, the position of the mental foramen of criteria one or anterior to the lower first premolar, two or in line with the lower first premolar, and six or in line with the mesiobuccal root of the lower first molar could not be found. Supriyadi et al. (2012) stated that other factors can cause differences in the position of the mental foramen, namely, differences in the size of the mandibular arch, race/ethnicity, ethnicity, and craniofacial type.³

In this study, each involved two categorical variables, so the data analysis was not normally distributed, and a non-parametric test analysis was carried out using the Mann-Whitney test to determine the difference between position and gender while to find out the difference between left and right positions by gender using Chi-Square. Based on the results of the research that has been done, the results show that the relationship between the position of the mental foramen, both right and left, on panoramic radiographs based on gender shows that there is no significant difference between men and women because the p value > 0.05 . It means that gender does not affect the location of the mental foramen in this study. It is supported by previous research by Thakare et al. (2016), evaluation of the position of the mental foramen based on panoramic radiographs in Pune residents showed that there was no

difference in the position of the mental foramen in the horizontal and vertical planes based on gender.⁷ This is also the same in the study of Ahmed Chkoura et al. (2013), showing that the position of the mental foramen of the Moroccan population is not influenced by gender.⁸

This study found that the position of the mental foramen was symmetrical, both left and right, with a percentage of 52.3%, while those that were not symmetrical obtained a percentage of 47.7%. However, there was no significant difference between the position of the left and right mental foramen based on gender because the p-value was > 0.05 . It is also supported by the research of Anshuman et al. (2013) conducted on the population of Rajasthan, India, which found that the location of the mental foramen was symmetrical, both left and right, with a percentage of 62.8%.⁹ However, in contrast to the research of Bello SA et al. (2018) conducted on the population of Nigeria, Africa, it was found that the location of the mental foramen was more asymmetrical, with a percentage of 51.3%.¹³ no literature reveals 100% symmetry between the positions of the two mental foramen. It indicates that the mental foramen is not always symmetrical in every individual.

Based on the analysis test criteria of this study, H₀ is accepted, and H₁ is

rejected because the p-value > 0.05 . So, the hypothesis states that there is no difference in the position of the mental foramen between men and women and the position of the mental foramen between left and right on panoramic radiographs of patients at RSGM Unjani in 2021. At the time of the research, the overall radiograph data at RSGM Unjani was only obtained from June to December 2021 because there were problems with the computer system, so data from January to May 2021 was lost. In 2021, it is still in the midst of the Covid-19 pandemic, so the number of panoramic radiographs available at RSGM Unjani is still limited. Then the number of research objects between men and women is not balanced because it uses a purposive sampling method.

CONCLUSION

Based on the research conducted, it can be concluded that there is no significant difference in the position of the mental foramen between men and women and the position of the mental foramen between left and right on panoramic radiographs of patients aged 20-44 years at RSGM Unjani in 2021. Further research needs to be carried out with a more significant number of samples. It is hoped that other variables such as race, ethnicity, and other age groups can be added for further research.

CONFLICT OF INTEREST

There is no conflict of interest in writing this article.

ACKNOWLEDGEMENT

We want to express our gratitude to everyone who contributed to the study and writing of this publication.

REFERENCES

1. Manja CD, Makkelo MT. Posisi foramen mentalis pada mahasiswa suku batak ditinjau dari radiografi panoramik di FKG USU. B-Dent, J Kedokt Gigi Univ Baiturrahmah. 2018;2(2):82–7.
2. Indonesian THE, Of J, Science H. Posisi foramen mentalis pada suku jawa dan madura: penelitian radiografi. 2012;2(2).
3. Tahun SM, Fadhillah S, Mattalitti O, Lestari N, Pertiwisari KA, Bima L. Judul artikel perbedaan usia terhadap posisi foramen mentalis panoramik di RSGM TNI AL Yos. 2019;01(02):39–48.
4. Sperber GH. Craniofacial Development and Growth. 2001. 127–138 p.
5. Norton NS. Netter's Head and Neck Anatomy for Dentistry, Second Edition Overview and Topographic Anatomy. 2012. 437–50.
6. Kholilullah R, Wahyuni OR, Astuti ER. Prevalensi posisi dan tipe foramen mental melalui pengamatan radiograf panoramik pasien rsgm fkg universitas airangga (Maret - Mei 2015) (Prevalence position and type mental foramen through the observation a radiograph panoramic patients rsgm fkg airl. 2015;6(2):12–7.
7. Thakare S, Mhapuskar A, Hiremutt D, Giroh VR, Kalyanpur K, Alpna KR. Evaluation of the position of mental foramen for clinical and forensic significance in terms of gender in dentate subjects by digital panoramic radiographs. J Contemp Dent Pract. 2016;17(9):762–8.
8. Chkoura A, El Wady W. Position of the mental foramen in a Moroccan population: A radiographic study. Imaging Sci Dent. 2013;43(2):71–5.
9. Mahatma AS, Gandhi M, Road T. Radiographic Localization of Mental Foramen in a Selected Indian. Inf J Med Heal Sci. 2013;3(5):249–53.
10. Primasari A. Embriologi dan Tumbuh Kembang Rongga Mulut. Embriologi dan Tumbuh Kembang Rongga Mulut. 2018. 55–6, 70–85, 162–79.
11. Himammi AN, Hartomo BT. Kegunaan radiografi panoramik pada masa mixed dentition. J Radiol Dentomaksilofasial Indones. 2021;5(1):39.
12. Kasni. Evaluasi foramen mental

- berdasarkan jenis kelamin ditinjau secara radiografi panoramik. 2014.
13. Bello SA, Adeoye JA, Ighile N, Ikimi NU. Mental Foramen Size, Position and Symmetry in a Multi-Ethnic, Urban Black Population: Radiographic Evidence. *J Oral Maxillofac Res.* 2018;9(4).
 14. Becker FG, Cleary M, Team RM, Holtermann H, The D, Agenda N, et al. *Wheeler's Dental Anatomy, Physiology and Occlusion.* Vol. 7, Syria Studies. 2015. 245.
 15. Al-juboori MJ, Al-wakeel HA, Yun CM. Mental foramen location and its implication in dental treatment plan. 2014;2(March):35–42.
 16. Inriany N, Jubhari EH. All-on-4 implant treatment: common difficulties and methods for coping. *Makassar Dent J.* 2021;10(3):218–22.
 17. Torres MGG, de Valverde LF, Andion Vidal MT, Crusoé-Rebello IM. Accessory mental foramen: A rare anatomical variation detected by cone-beam computed tomography. *Imaging Sci Dent.* 2015;45(1):61–5.
 18. Mardiaty E, Astuti IA. Perawatan bedah ortognati pada maloklusi dentoskeletal kelas III dengan asimetri wajah dan canting oklusal rahang atas. 2021;32(3):164.
 19. Suryaprawira A. Superimposisi Sefalometri Pada Maloklusi Skeletal Kelas Iii Dengan Bedah Ortognatik. *J Ilm dan Teknol Kedokt Gigi.* 2019;15(1):25.
 20. Silva HF da, Marinho LF, Souza GA, Sverzut AT, Olate S, Asprino L, et al. About chin (Genioplasty) surgery. *Int J Morphol.* 2020;38(4):1120–7.
 21. Astuti R, Putri D. Angka Kejadian Fraktur Mandibula. 2015;1(2):1–14.
 22. Iannuci JM, Howerton LJ. *Dental Radiography - Principles and Techniques.* Elsevier. 2016. 1–482.
 23. White SC. *Essentials of Dental Radiography and Radiology.* Vol. 31, Dentomaxillofacial Radiology. 2002. 331–2.
 24. Public Health England (PHE) and Faculty of General Dental Practice (UK) (FGDP[UK]). *Guidance Notes for Dental Practitioners on the Safe Use of X-ray Equipment.* 2nd Edition. London UP and F 2020. *Guidance Notes for Dental Practitioners on the Safe Use of X-ray Equipment* 2nd Edition. 2020. 92–3.
 25. Sukmana BI. Radiografi di Bidang Kedokteran Gigi. Vol. 53, *Journal of Chemical Information and Modeling.* 2019. 22–4.
 26. Sandeep R, Burde K, Nandimath K. Evaluation of the Position of Mental Foramen and Its Correlation with Age in Selected Indian Population, Using Digital Panoramic Radiograph. *Int J Dent Sci Res.*

2015;3(4):87–91.

27. Singal K, Sharma S. Gender determination by mental foramen using linear measurements on radiographs: A study in haryana population. *Indian J Forensic Med Toxicol.* 2016;10(1):44–9.