

**FISTULA MANAGEMENT DUE TO CHRONIC  
INFECTION OF RADICULAR CYST  
(PENATALAKSANAAN FISTULA AKIBAT INFEKSI  
KRONIS PADA KISTA RADIKULAR)**

Tichvy Tammama<sup>1\*</sup>, Winda Afrilia Megayanti<sup>1</sup>

<sup>1</sup>Department of Oral Surgery and Maxillofacial Faculty of Dentistry,  
Universitas Jenderal Achmad Yani Cimahi Indonesia

\*Corresponding author

*tichvy@yahoo.com*

*JHDS.unjani.ac.id/jite*  
*Doi:10.xxxx/jite*

**Article History**  
*Received: 15/09/2021*  
*Accepted: 30/09/2021*

**ABSTRACT**

A radicular cyst is the most common odontogenic cyst that arises from the epithelial residues in the periodontal ligament due to periapical periodontitis following death and necrosis of the pulp. A fistula may form a cyst with a pulp infection that produces pus and seeks its way out to the gingival surface to create a canal. The purpose of this case report is to report the management of a patient with a chronically infected radicular cyst with fistula while retaining the involved tooth. A case report was a 13-year-old female patient who came to Department Oral Surgery of a hospital with a complaint of a lump in the front gum and palate that didn't heal for two years ago and often discharged pus. Intraoral examination showed a lump in the gingiva and palate with fistula in the interdental gingiva of teeth 11-12 with soft consistency and pain with palpation. Panoramic results showed characteristics of the radicular cyst at the 13-11 tooth region. The lesion is diagnosed as a chronic infection of a radicular cyst due to pulp necrosis in teeth 12-11 with interdental fistulas. Biopsy enucleation of the cyst was performed with teeth preservation. The patient was advised to have regular check-ups. On the sixth month of control, the surgical wound was good, without any complaints and signs of recurrence. The result is that a radicular cyst can become chronically infected and form a fistula that oozes pus into the oral cavity. The cyst can be treated with enucleation

biopsy and fistulectomy with the preservation, without any recurrences.

**Keywords:** cyst; enucleation; fistula; infection; radicular

### **ABSTRAK**

*Kista radikular merupakan kista odontogenik yang paling sering timbul dari sisa epitel ligamen periodontal akibat periodontitis apikalis pada gigi yang nekrosis. Fistula dapat terbentuk pada kista apabila gigi tersebut mengalami infeksi dan menghasilkan pus yang mencari jalan keluar melalui gingiva sehingga terbentuk saluran. Tujuan laporan kasus ini untuk menjelaskan penatalaksanaan pasien dengan kista radikular yang mengalami infeksi kronis disertai fistula dengan tetap mempertahankan gigi yang terlibat. Laporan Kasus: Pasien anak perempuan berusia 13 tahun datang ke bagian Bedah Mulut di sebuah Rumah Sakit dengan keluhan terdapat benjolan di gusi depan dan palatum yang tidak sembuh sejak 2 tahun yang lalu serta sering mengeluarkan nanah. Pada pemeriksaan intraoral tampak benjolan pada gingiva dan palatum disertai fistula pada gingiva interdental regio gigi 11-12 dengan konsistensi lunak dan nyeri saat ditekan. Pemeriksaan panoramik memperlihatkan gambaran kista radikular pada regio gigi 13-11. Lesi didiagnosis sebagai kista radikular terinfeksi kronis akibat nekrosis pulpa gigi 12, 11 disertai fistula pada interdental 12-11. Dilakukan biopsi enukleasi kista dengan tetap mempertahankan gigi yang terlibat. Pasien disarankan untuk kontrol berkala. Pada kontrol 6 bulan, luka tampak baik, tanpa keluhan dan tanda-tanda rekurensi. Kista radikular dapat mengalami infeksi kronis hingga terbentuk fistula yang mengeluarkan pus ke rongga mulut. Umumnya kista dapat ditangani dengan biopsi enukleasi dengan tetap mempertahankan gigi yang terlibat, tanpa rekurensi.*

**Kata kunci:** enukleasi; fistula; kista radikular; infeksi;

### **INTRODUCTION**

A cyst is a pathologically sac-like pocket of

membranous tissue filled with fluid or semi-fluid that develops abnormally in space or

organs.<sup>1</sup> Radicular cyst is the most common in odontogenic cysts. In one of the jaws cysts come from the remnants, epithelial Malassez of the periodontal ligament due to chronic inflammation or irritation from root canal infection. It begins with periapical granuloma formation as a result of bacterial infection and pulp necrosis.<sup>1,2</sup> Radicular cysts have the highest frequency in the third decade of life, and there are many cases involving the fourth and fifth decades of life. This case is more common in men than women, with maxillary 60% and mandibular 40%. Most of these cases occur in the maxillary anterior region, which is more vulnerable to traumatic injury and caries, where the incisors and canines are generally the most common locations.<sup>3,4</sup>

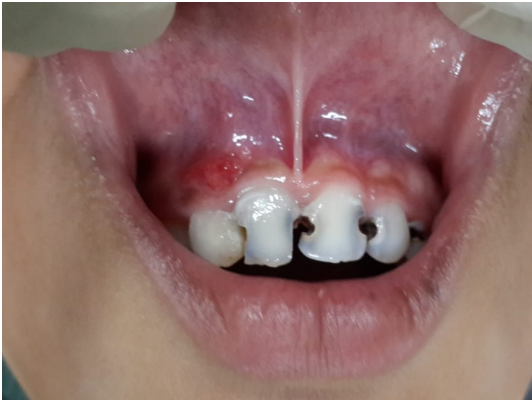Radicular cysts are found chiefly incidentally when radiographs are performed for nonvital teeth. Radicular cysts are asymptomatic, and patients usually complain of swelling that gets bigger over time and disturbing aesthetically and functionally, involves mobility and migration of other teeth.<sup>1,4</sup> The radiography appearance is round or oval with radiolucent content surrounded by a radiopaque border that extends the lamina dura of the involved tooth.<sup>4</sup> The pathogenesis of the cyst consists of three phases, namely phase 1, the initiation phase, phase 2, which the cyst begins to form, and

phase 3, the developmental stage of the cyst until it reaches a large size.<sup>4</sup> Surgical procedures for the management of radicular cysts may include extraction, enucleation, and marsupialization, and non-surgical procedures in some cases may include root canal treatment.<sup>5,6,7</sup>

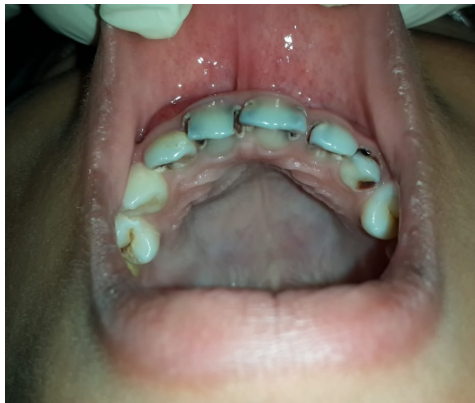In this case report, the authors describe a case in a 13-year-old female patient with a diagnosis of an infected radicular cyst due to pulp necrosis of teeth 12, 11 with interdental fistulas 12-11 with extirpation biopsy and fistulectomy under general narcotics. It is followed by antibiotic medication and anti-inflammatory and periodic control in a week.

## CASE REPORT

A 13-year-old female patient came to Oral and Maxillofacial Surgery Clinic of AMC Hospital, Bandung, with her mother complaining of a lump in the front gum that didn't heal since two years ago and was often discharged pus. The patient also complains of frequent swelling of the palate that comes and goes. The results of the intraoral examination showed fistulas in the interdental region of teeth 11-12 (Figure 1) and swelling in the palatal areas of 13-11 with a soft consistency and pain when it got pressed (Figure 2). On aspiration examination, there was a small amount of clear fluid mixed with pus.



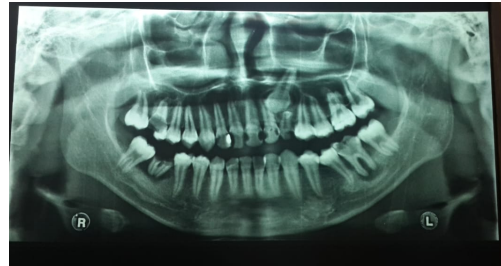
**Figure 1.** Intraoral examination showed a lump in the gum of the 11-12 tooth region with fistula.



**Figure 2.** Intraoral examination showed swelling in the palatal of 11-13 tooth region.

The patient underwent a panoramic radiological examination that shows radiolucent on the mesial and distal of the crown 11-12 tooth from the enamel to the pulp. It was a radiopaque image resembling restorative material in the mesial and radiolucent on the distal of the crown of 13 teeth from the enamel to the pulp. There is a round radiolucent appearance on the periapical of the 11-13 roots of the tooth

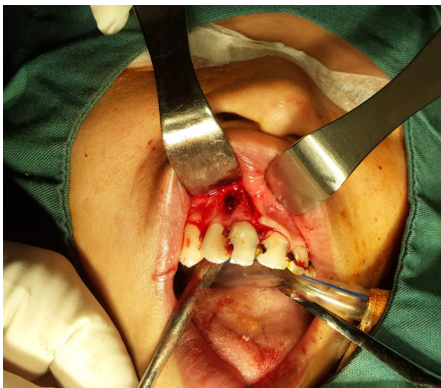with a size of 2x1 cm with firm boundaries and resembling a cyst (Figure 3). Based on the examination results, a clinical diagnosis is a chronic infection of a radicular cyst due to pulp necrosis of teeth 12, 11 with interdental fistula.



**Figure 3.** Panoramic results showed characteristics of the radicular cyst at 13-11 tooth region.

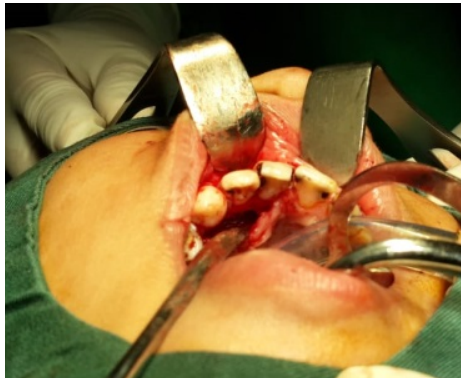The treatment performed on the patient was extirpatory biopsy and fistulectomy under general narcotics. The position of the patient is in a lying place when the operator will carry out the treatment. The treatment consists of several stages: extraoral and intraoral aseptic and antiseptic using povidone iodine, insertion of an oropharynx pack, and infiltration anesthesia on the labial and palatal with a syringe containing pehacaine. After the anesthetic condition was achieved, the lesion was aspirated, and one cc of pus was obtained. The operator did a triangular flap on the gingiva 11-13, then dissected and found a cyst wall and fistula on the labial side with size 0,7x0,7x0,5 cm with pus coming out. An exploration and excision of

the fistula are performed on the labial side (Figure 4).



**Figure 4.** Post fistulectomy, fistula with bone base appear.

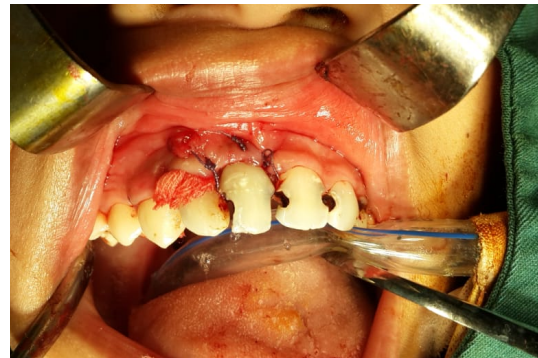Next, do a flap envelope on the palate of the 14-21 tooth region, dissect and find a cyst capsule wall with size 2x1,5x1,5 cm filled with pus, then explore and remove the cyst wall are performed (Figure 5).



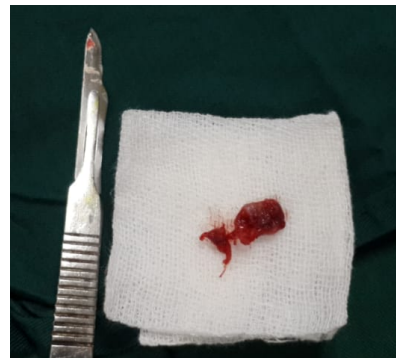**Figure 5.** Post enucleation of the cyst on a palatal view.

After completion, control bleeding and debridement in the post-enucleated area with betadine and 0,9% NaCl. Insert a rolled gauze that has been given chloramphenicol into the post enucleation hole and suture the wound (Figure 6); the procedure is complete. The specimen in the form of a cyst wall that had been taken was subjected

to further examination at Pathology Anatomy (Figure 7).



**Figure 6.** Wound cleaning and insertion of gauze into the hole.



**Figure 7.** Specimen of cyst capsule with fistula.

On the fourth day of control, there was no complaint from the patient, the surgical wound was good, and the gauze was removed. On the seventh day of power, the patient histopathological examination result concluded an infected radicular cyst. There was no complaint; the surgical wound was good, then stitches could be opened. The patient came back for control in the sixth month without any complaints and signs of recurrence.

## DISCUSSION

A radicular cyst is the most common cyst in odontogenic cysts. It arises from the epithelial residues in the periodontal ligament due to periapical periodontitis following death and necrosis of the pulp. Cysts arising in this way are found most commonly at the apices of the involved teeth but may also be found on the lateral aspects of the roots concerning lateral accessory root canals.<sup>8</sup>

Many radicular cysts are symptomless and are discovered when radiographs are taken of teeth with nonvital pulps.<sup>8</sup> The case of radicular cyst reported this time happened to a 13-year-old female patient with a complaint of a lump in the front gum and the palate for two years ago and often discharge pus. The clinical picture showed fistula in the interdental region of 11-12 and swelling in the palatal area 13-11 with tender consistency and pain when pressed.

Radicular cysts are the most common cause of swelling of the jaws, and slowly enlarging swellings complain. At first, the enlargement is bony hard, but as the cyst increases in size, the covering bone becomes very thin despite subperiosteal bone deposition, and the swelling then exhibits springiness. Only when the cyst has completely eroded the bone will the lesion be fluctuant. There may be buccal or palatal enlargement in the maxilla, whereas, in the

mandible, it is usually labial or buccal and rarely lingual.<sup>8</sup>

Radicular cysts most likely result from bacterial infection of pulp necrosis, bacteria that initiate inflammation in the pulp and periapical tissues produce chemical mediators that cause periapical soft tissue proliferation and stimulate osteoclastic activity, inflammatory cell cytokines, and growth factors released during apical periodontitis that can stimulate residual epithelial cells Malassez in the apical periodontal ligament to develop and form cysts.<sup>9,10</sup>

Pain and infection are other clinical features of some radicular cysts. It is often said that radicular cysts are painless unless infected. However, there seems to be no clear correlation between infection and symptoms. Some patients complain of pain, although no evidence of infection is found clinically, and no evidence of acute inflammation is seen histologically after the cyst has been removed. Likewise, some patients have clinically infected and histologically inflamed cysts which are not painful.<sup>8</sup>

Occasionally, a fistula may lead from the cyst cavity to the oral mucosa.<sup>8</sup> A fistula is an abnormal canal between two organs with the outer surface as drainage because the periapical pus seeks its way out to the gingival surface. The fistula is lined

with granulation tissue and inflammatory cells and may resolve once the infection of the pulp and necrotic tissue in the root canal has resolved.<sup>11</sup>

On aspiration examination of the patient, there was a small amount of clear fluid mixed with pus. The contents of cyst cavities were subject to an osmotic imbalance with the surrounding tissues because of the absence of lymphatic drainage. Lytic products of the epithelial and inflammatory cells in the cyst cavity provided more significant numbers of smaller molecules, which raised the osmotic pressure of the cyst fluid. Deposits of cholesterol crystal are found in many radicular cysts, but by no means in all. The primary source of cholesterol was from disintegrating red blood cells in a form that readily crystallizes in the tissues. Cholesterol from this source and serum accumulates in the tissues because of the relative inaccessibility of normal lymphatic drainage.<sup>8</sup>

The inflammatory cell infiltrates in the proliferating epithelial linings consist predominantly of polymorphonuclear leucocytes, whereas the adjacent fibrous capsule is infiltrated mainly by chronic inflammatory cells. The proliferation epithelial linings show a considerable degree of spongiosis. The polymorphonuclear leucocytes migrate

along these channels and into the cyst cavity through interepithelial spaces on the luminal surface. As the cyst enlarges, the wall may become less inflamed and fibrous. It is the most noticeable distance from the apex of the tooth.<sup>8</sup>

The patient radiographic appearance showed a radiolucent image on the mesial and distal of the 11, 12 tooth crown from the enamel to the pulp. There is a radiopaque image resembling a restorative material in the mesial and radiolucent on the distal of the 11-13 tooth from the enamel to the pulp and a round radiolucent image on the periapical of the 11-13 tooth roots with size 2x1 cm with firm boundaries and resembling a cyst.

The radiological appearance description of radicular cysts is that they are round or ovoid. Radiolucency are surrounded by a narrow radiopaque margin that extends from the lamina dura of the involved tooth. In infected cysts, the radiopaque margin may not be present. There is no correlation between the loss of radiographic certification and the increasing intensity of acute inflammation. Root resorption is not often seen on routine radiographs, but it may occur.<sup>8</sup>

Treatment of radicular cysts can be done by root canal treatment, extraction, enucleation, marsupialization.<sup>11</sup> In this case, the patient's cyst was treated by

enucleation to extirpate the cyst. Enucleation is the primary choice in the treatment of most odontogenic cysts. Enucleation is the process by which the total removal of a cystic lesion is achieved. It means a shelling-out of the entire cystic lesion without rupture. Enucleating cysts should be performed to remove the cyst in one piece without fragmentation by removing the whole cyst, including the epithelium and the capsule, from the bone wall without leaving any pathological tissue.<sup>12</sup>

The main advantage of enucleation is that pathologic examination of the entire cyst can be undertaken. Enucleation treats the lesion so that once the mucoperiosteal access flap has healed, the patient is no longer bothered by the cystic cavity.<sup>12</sup>

Once access to a cyst has been achieved through an osseous window, the cyst begins to enucleate. A thin-bladed curette is used for cleaving the connective tissue layer of the cystic wall from the bony cavity. The curette then be used with the concave surface should always keep facing the bony cavity; the edge of the convex surface performs the stripping of the cyst, then the cyst separates form the bony cavity. Once the cyst has been removed, the bony cavity should be inspected for remnants of tissue.<sup>12</sup> Fistulectomy was performed as a treatment to completely excise the fistula

tract at the labial 13, 12 interdental gingivae.

It was irrigating and drying the cavity with gauze aids in visualizing the entire bony cavity. Residual tissue is removed with curettes. The bony edges of the defect should be smoothed with a file before closure. A cyst surrounding tooth roots or in inaccessible areas of the jaws requires aggressive curettage, which is necessary to remove fragments of the cystic wall.<sup>12</sup>

After enucleation, the wound should be irrigated with sterile saline. An appropriate length of strip gauze lightly impregnated with antibiotic ointment should be gently packed into the cavity to prevent dehiscence and infection. A watertight primary closure should be obtained with the sutures. In this case, we used polyglycolic acid 4-0 to safely decompose the surgical string in the body without leaving suture marks. The bony cavity fills with a blood clot, which then organizes over time. Granulation tissue is seen on the bony walls in 3 to 4 days and slowly obliterates the cavity and obviates the need for packing. The oral epithelium then closes over the top of the opening, and osseous healing progresses. Jaws that have been expanded by cysts slowly remodel themselves to a more normal contour.<sup>12</sup>

Other medical therapy was given to



patients, such as an antibiotic like ceftriaxone. It was to prevent postoperative bacterial infections; ceftriaxone was chosen because it has a large spectrum that works by inhibiting the synthesis of microbial cell walls.<sup>13</sup>

Anti-inflammatory drugs were given to patients, such as dexamethasone and ketorolac. It was to prevent inflammation and pain in the oral mucosa in the surgical area. Dexamethasone was chosen as a corticosteroid drug that can inhibit phospholipase A2. It causes prostaglandins and leukotrienes to form, disrupts inflammatory mediators, and reduces tissue edema. Ketorolac was chosen as a non-steroidal anti-inflammatory drug that could inhibit prostaglandin production, and ketorolac is commonly used to treat moderate to severe pain.<sup>14,15</sup>

Ranitidine can prevent irritation of the stomach due to excess acid production. Some pain relievers have side effects on the stomach in excess acid production or irritation, so ranitidine was chosen as protection against the abdomen.<sup>16</sup>

The patient took control on the fourth day for the release of the gauze. On the third day, primary wound healing occurred. It was a process of epithelialization and connective tissue deposition, and epithelialization usually that happened within 72 hours risk of infection was lower.

Gauze that has been given chloramphenicol is useful as antibiotic therapy in the wound area to prevent disease after surgery.

The opening of the sutures was carried out on the seventh day, where the wound healing process on the seventh day had an excellent reepithelialization process, and the new epithelial tissue formed had matured. A new layer of corneum was usually clearly visible.

## **CONCLUSION**

In this case report, the patient had a chronic infection of a radicular cyst due to pulp necrosis of teeth 12, 11 with interdental fistulas 12, 11. Surgical management has been done by extirpating biopsy. It was with a fistulectomy in general narcotics, and the healing was good without any complications.

## **CONFLICT OF INTEREST**

We declare that there is no conflict of interest in the scientific articles.

## **ACKNOWLEDGEMENT**

Our gratitude goes to the Faculty of Dentistry, Unjani, and AMC Hospital professionals who have helped with this case report and draft papers.

## **REFERENCES**

1. Mawardi MH, Chandha H. Penatalaksanaan kista radikuler pada maksila anterior secara enukleasi.

- Journal of Dentomaxillofacial Science. 2016;1(1).
2. Nasser A, Baby G, Alex V, John H, Anish N. Radicular cyst. *Anoor Journal for Scientific Research*. 2018 Sept-Dec;1(1).
  3. Jagtap R, Shuff N, Bawazir M, Garrido MB, Bhattacharyya I, Hansen M. A Rare presentation of radicular cyst: a case report and review of literature. *EADS*. 2021;48(1).
  4. Izzati AF. Etiologi dan patogenesis kista radikuler. *Repository Universitas Padjajaran*. 2020. p.2-3.
  5. Jimson S, Sankari L, Bhanumurthy L, Julius A. Radicular cyst of jaw: A Review. *Indian Journal of Public Health Research and Development*. 2019;10(11).
  6. Khare A, Dayma A. Management of radicular cyst: a clinical case report. *Journal of Orofacial Research*. 2019 Apr-Jun;8(2).
  7. Ebenezer V, Asir VD. Surgical management of radicular cyst – a case report. *European Journal of Molecular & Clinical Medicine*. 2020;20(20).
  8. Shear M, Speight PM. *Cysts of the oral and maxillofacial regions*. 4th ed. 2007. Munksgaard: Blackwell. p.123-40.
  9. Lin L, Ricucci D, Kahler B. Radicular cyst review. *JSM Dent Surg*. 2017;2(2).
  10. Razak A. Keuntungan dan kerugian marsupialisasi dibandingkan enukleasi serta komplikasi yang dapat terjadi. *Repository Trisakti*. 2019.
  11. Rakhma T, Untara R. Perawatan saluran akar satu kunjungan pada gigi molar pertama kanan mandibula nekrosis pulpa dengan abses periapikal dan fistula. *Maj Ked Gi*. 2016; 18(1).
  12. Hupp JR, Ellis E, Tucker MR. *Contemporary oral and maxillofacial surgery*. 7th ed. Philadelphia: Elsevier. p.478
  13. Abdurrachman, Febrina E. Evaluasi Penggunaan antibiotik pada pasien anak penderita demam tifoid di Rumah Sakit Al-Islam Bandung. *Jurnal Farmaka*. 2018; 16(2).
  14. Samuel S, Nguyen T, Choi H. Pharmacologic characteristic of corticosteroid. *Journal of Neurocritical Care*. 2017.
  15. Handayani S, Arifin H, Manjas M. Kajian penggunaan analgetik pada pasien pasca bedah fraktur di *Trauma Center RSUP DR. M. Djamil Padang*. *Jurnal Sains Farmasi & Klinis*. 2019.
  16. Amrulloh F, Utami N. Hubungan konsumsi OAINS terhadap gastritis. *Jurnal Universitas Lampung*. 2016; 5(5)