

## MINI DENTAL IMPLANT AS TREATMENT OF CHOICE IN A LATE TOOTH AVULSION WITH BONE RESORPTION: CASE REPORT

### (MINI DENTAL IMPLAN SEBAGAI PERAWATAN PILIHAN PADA AVULSI GIGI LANJUT DENGAN RESORBSI TULANG: LAPORAN KASUS)

Hans Goenawan<sup>1\*</sup>, Maria Goreti Widiastuti<sup>1</sup>, Muhammad Fuadi<sup>2</sup>, Rizqan Maulana<sup>2</sup>

<sup>1</sup>Department of Oral and Maxillofacial Surgery, Faculty of Dentistry, Universitas Gadjah Mada, Yogyakarta, Indonesia

<sup>2</sup>Resident of Oral and Maxillofacial Surgery, Faculty of Dentistry, Universitas Gadjah Mada, Yogyakarta, Indonesia

\*Corresponding author

[hans\\_goenawan@yahoo.com](mailto:hans_goenawan@yahoo.com)

*JHDS.unjani.ac.id/jite*  
*Doi: 10.54052/jhds.*

**Article History**  
*Received: 12/10/2022*  
*Accepted: 09/11/2022*

#### ABSTRACT

Tooth avulsion is a severe condition of traumatic dental injury. The long-time effect of untreated tooth avulsion is alveolar bone loss. The mini dental implant can be a treatment for single tooth replacement in a late tooth avulsion with bone resorption. The purpose of this study is to present a case report of the mini dental implant in a late avulsion of an anterior maxillary tooth without bone augmentation. Thirty years old male patients came to clinic with the left upper central incisor avulsed due to a traffic accident three years before. There has been mild vertical and horizontal bone resorption and diastemas. He wanted to replace the missing tooth with a fixed denture, and the patient refused any bone augmentation. The mini dental implant was an alternative treatment for this case. Orthodontic treatment was performed to regain space before

mini dental implant placement because some teeth had been migrated, causing some diastemas. After seven months of orthodontic treatment, we inserted a 3.0 x 13.0 mm nobel active implant bone level and installed the healing abutment. The prosthetic crown was screwed carefully using a manual torque wrench with a maximum torque force not exceeding 15 Ncm. The mini dental implant could be a treatment for a late avulsion case without bone augmentation.

**Keywords:** mini dental implant; traumatic dental injury

### **ABSTRAK**

*Avulsi gigi adalah kondisi parah dari cedera gigi traumatik. Efek jangka panjang atau tidak dirawatnya avulsi gigi adalah kehilangan tulang alveolar. Implan gigi mini dapat menjadi pengobatan pilihan untuk penggantian gigi tunggal pada avulsi gigi lanjut dengan resorpsi tulang. Tujuan dari penelitian ini adalah untuk menyajikan laporan kasus implan gigi mini pada avulsi lanjut gigi anterior rahang atas tanpa augmentasi tulang. Pasien laki-laki 30 tahun datang ke Klinik dengan gigi insisivus sentral kiri atas avulsi karena kecelakaan lalu lintas 3 tahun yang lalu. Telah terjadi resorpsi tulang dan diastema vertikal dan horizontal ringan. Pasien ingin mengganti gigi yang hilang dengan gigi tiruan cekat. Pasien menolak untuk setiap augmentasi tulang. Implan gigi mini merupakan pengobatan alternatif untuk kasus ini. Perawatan ortodontik dilakukan untuk mendapatkan kembali ruang sebelum penempatan implan gigi mini karena beberapa gigi telah bermigrasi menyebabkan beberapa diastema. Setelah 7 bulan perawatan Ortodontik, operator memasukkan level tulang implan Nobel Aktif 3,0 x 13,0 mm dan memasang penyangga penyembuhan. Mahkota Prostetik disekrup dengan hati-hati menggunakan kunci torsi manual dengan gaya torsi maksimum tidak melebihi 15 Ncm. Implan gigi mini dapat menjadi pengobatan pilihan untuk kasus avulsi lanjut tanpa augmentasi tulang.*

*Kata kunci: implan gigi mini; resorpsi tulang*

## **INTRODUCTION**

Traumatic dental injuries are relatively typical cases in our daily dental practice.<sup>1</sup> Traumatic Dental Injuries (TDI) cause immediate damage in a patient with a negative impact on quality of life. Treatment plans often cover multidisciplinary, lengthy and involve a team of dentists and specialists who solve various problems.<sup>2</sup> Severe trauma in traumatic dental injuries can result in a significant loss of teeth and associated soft and hard tissues. The teeth often remain show signs of significant damage and may be unrestorable. Others may have been luxated or avulsed and subsequently re-implanted, which can result in a compromised long-term prognosis.<sup>3</sup>

The simplest solution to replace an avulsion tooth is often to provide a removable partial denture, which can replace the teeth and the missing hard and soft tissues in the form of a pink acrylic flange. However, problems could arise with this treatment and lead to functional issues and discomfort. Many patients are reluctant to accept a removable dental prosthesis and often seek a fixed solution for better acceptance. Large edentulous spans caused by the missing of several teeth may rule out any form of conventional bridgework. For

these patients, dental implants are the only predictable fixed option.<sup>3</sup>

Endosseous dental implant rehabilitation can provide partially or wholly edentulous patients with function and esthetic like natural dentition while preserving adjacent teeth. In clinical restoration situations where residual dentitions are healthy, and there are no systemic contraindications, dental implant therapy may represent the highest standard of care for tooth replacement. Most implants fall in the "standard diameter" range of 3.5 mm to 4.3 mm. When placing dental implants in partially edentulous patients, it has been recommended to maintain 2 mm to 3 mm of available space between the surface of the implant and the residual dentition to avoid impinging or damaging the periodontal ligaments of the adjacent teeth. Unfortunately, some patients have been traditionally excluded from the benefits of implant therapy because they lacked adequate mesiodistal edentulous space to accommodate even a narrow-diameter implant.<sup>5</sup>

Implants with diameters 3.0 mm (i.e., mini-implant) were initially developed for placement in conjunction with standard diameter implants to stabilize and retain an interim prosthesis during the healing phase.

Other research has suggested that the pull-out strength of Endosseous implants may be based on the length rather than the diameter of the implant. Histologic analysis has shown that mini-implants undergo osseointegration comparable to that of larger-diameter implants. These findings have led some clinicians to advocate the use of mini-implant to support and/or retain definitive prostheses.<sup>5</sup>

This article will discuss on the clinical use of mini dental implant as treatment choice without bone augmentation for tooth loss caused of the late avulsion in a traumatic dental injury (TDI).

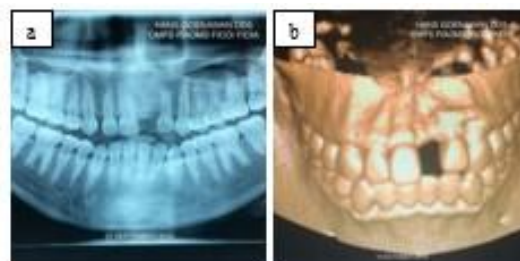#### CASE REPORT

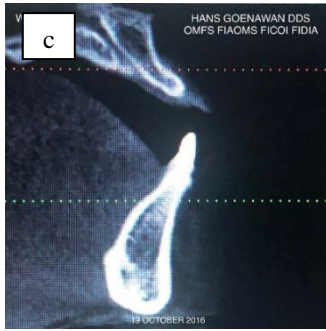
A 30-year-old male came to Dr Hans Oral Surgery and Dental Implant Clinic in South Tangerang, Indonesia. He wanted to consult his anterior maxilla avulsion tooth due to a traffic accident in August 2013. After he was stabilized medically, he was referred to a dentist for prosthodontic evaluation and rehabilitation management.

The patient was offered a removable denture or bridge to replace the avulsion tooth, but the patient refused. The patient did not attend any treatment until he came to the Clinic in September 2016 seeking consultation on the possibility of a fixed denture. A complete extraoral and

intraoral examination revealed #21 missing tooth, #13 and #12 diastema. We referred the patient for an OPG and 3D-CBCT examination.

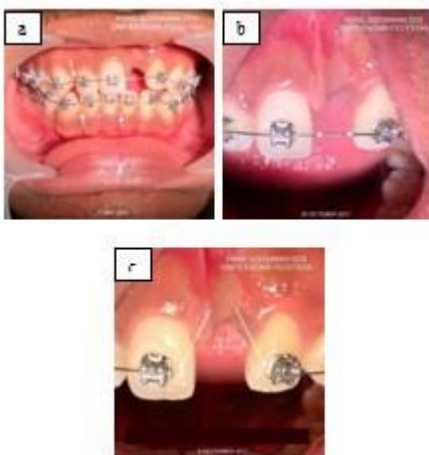Initial Panoramic X-ray showed a drifting of teeth #12 and #11 to the left side due to #21 missing for more than three years (Figure 1a). From the 3D-CBCT examination, we noticed mild vertical and horizontal bone resorption (Figure 1b). The patient then described the implant as the treatment of choice concerning the missing tooth being in the esthetic zone. He agreed to the treatment but refused the bone shell technique augmentation, taking the bone plate from the retromolar to maximize bone dimension and facilitate a 4.3 or 5.0 mm implant. According to this condition mini-implant then the only solution. The patient was also informed of the advantages and disadvantages of using a mini-implant without augmentation.





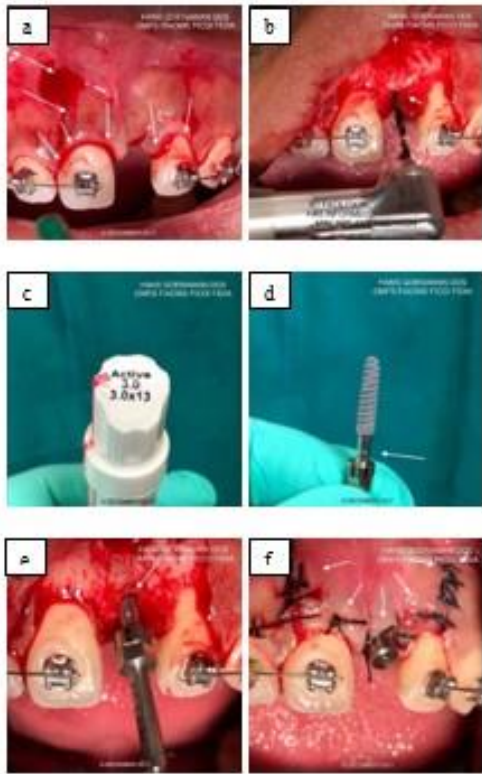**Figure 1.** (a) initial OPG, (b) 3D-CBCT showed #21 missing tooth, (c) CBCT cross-sectional view. Twenty-one interacts relation—mild bone resorption due to avulsion three years before.

Orthodontic treatment was performed on both arches to maintain spaces and harmonize the occlusion. We decided to treat orthodontic treatment to gain more space for the #21 region and to close #13 and #12 diastema (figure 2a). Orthodontic braces and arch wire remain in place until the implant prosthetic is inserted and before Prosthetic Crown, to prevent relapse and space closing (figure 2b). Seven months later, optimal space has enough gained, and arch wire cut to allow easy #21 implantation (figure 2c).



**Figure 2.** (a) initial orthodontic treatment, (b) orthodontic treatment gained equal 21 space to 11 for implantation, (c) optimal space after 7 months orthodontic treatment.

A trapezoidal flap design extended from the #21 crestal to the #11 and #22 vertical flap (figure 3a). Open the flap total thickness carefully, showing mild resorption of alveolar bone. Drill #21 step by step and keep the angulation and position (figure 3b). Insert Nobel Active implant 3.0 x 13.0 mm (figure 3c-3d). Hold the implant with implant driver 3.0 and put the manual ratchet adapter into the implant driver. The implant was inserted manually and continued with a manual ratchet torque wrench (figure 3e). Implant inserted bone level. Tension-free suture and put healing abutment (figure 3f). The patient refused to use temporary removable dentures for chewing but agreed for the esthetic reason with relief in the anatomic part to prevent any pressure. A healing abutment was then installed.

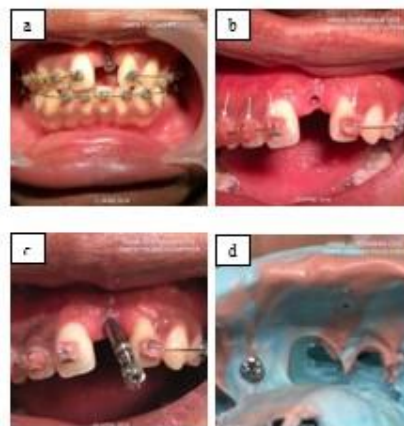

**Figure 3.** (a) trapezoidal flap incision, (b) drilling #21, (c) Nobel active implant 3.0x13.0 mm, (d) hold implant driver 3.0, put manual ratchet adapter, (e) implant insert manually, (f) tension-free suture and healing abutment.

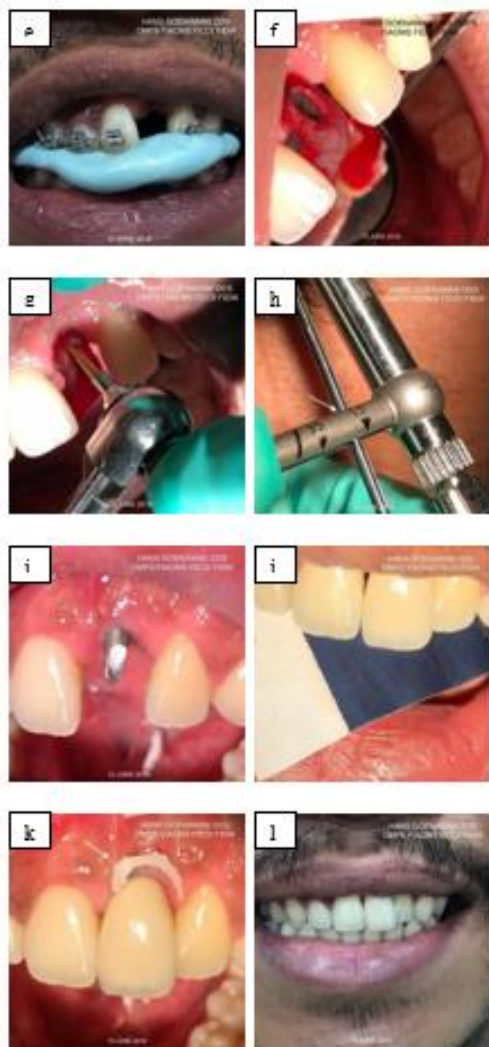
Six months after implantation, the patient maintains the orthodontic braces to prevent any space from closing. For prosthetic treatment the arch wire was then cut and ready for prosthetic treatment. Healing abutment removed and preparation for impression. Orthodontic braces were wax boxed to prevent undercuts during the impression. Impression coping open tray installed. Double impression with imprint coping available tray inside impression material. Centric occlusion bite registration using putty impression material. Then,

choose the shade of the prosthetic Crown.

Insert the Prosthetic Crown into the implant guided by the insertion path jig. A secure abutment screw can be inserted safely using a manual torque wrench to avoid the implant's tension. According to the manual Nobel Active Implant Guidance, the maximum torque force for a 3.0 Nobel Active prosthetic abutment screw is not to exceed 15 Ncm. Remove the prosthetic insertion path jig. Try prosthetic crown insertion without cement and check the centric occlusion. We were prepared to cement the prosthetic Crown if there was no traumatic occlusion. We filled the abutment hole with gutta-percha to safely cover the abutment screw head. Cementing the prosthetic Crown with resin cement removed all cement excess at the palatal and buccal sides. Light-cured resin cement at the buccal side for 10 seconds, then carefully clean the excess. Continue light curing for another 20 seconds. Remove all excess cement to avoid any irritation to the gingiva.







**Figure 4.** (a) six months after implantation, (b) remove healing abutment, (c) impression coping open tray installed, (d) double impression with compression coping, (e) centric occlusion bite registration, (f) insert metal abutment into implant guided by the insertion path jig, (g) secure abutment screw using a manual torque wrench, (h) maximum torque force not exceed than 15nm, (i) fill abutment hole with gutta-percha, (j) occlusal bite check, (k) labial cement excess cleaned, (l) looks natural and mimicking to the adjacent teeth.

## DISCUSSION

Tooth avulsion is defined as the complete loss of a tooth out of the alveolar bone socket due to an accident and represents a severe traumatic dental injury (TDI). Tooth avulsion mainly affects incisors teeth.<sup>6</sup> Permanent teeth should be placed in an appropriate medium and transported with the patient for replantation. The treatment of choice for an avulsed tooth is to have it immediately cleansed (if debris is present) and replaced in the socket<sup>7,8</sup>. In this case, the tooth was not replanted because the avulsion tooth was not found after the patient had an accident.

The treatment options to replace a single tooth are partial removable denture, adhesive bridgework, conventional bridgework, orthodontic closure, and implant-stabilized Crown.<sup>9,10</sup> The patient refused treatment options of a removable denture and bridgework. An alternative was an orthodontic treatment to close the space, but this option was not always feasible. In the recent literature, there were still doubts regarding the redistribution of arched spaces.<sup>11,12</sup> In cases where it was impossible to perform either of these other treatments, an alternative involves dental implants.

One effect of tooth avulsion for a long time is loss of alveolar bone. When a tooth is avulsed or extracted, bone loss will occur mainly over the first six months after

extraction (40 percent of bone height and 60 percent of bone width). It was a continuous process with a rate of 0.25–0.5 percent of bone loss per year.<sup>13</sup> After three years, the central incisor maxilla avulsed, and vertical and horizontal bone resorption occurs. In cases where the loss of alveolar bone progressed for a long time, this condition might require bone augmentation, possibly using guided bone regeneration or other techniques before dental implants<sup>4,13</sup>. On the implant's facial and palatal/lingual areas, a minimum of 1 mm of bone was required around the implant. A minimum of 6 mm bone bed is necessary to place a standard-size implant. Smaller diameter implants can be placed in areas with reduced bone, or bone grafting or guided bone regeneration can be used.<sup>14</sup> When the patient refused bone augmentation, alternatively, a new treatment concept for bone resorption, the mini dental implant was the alternative.

The width of the implant is ideally suited for replacing upper central incisors, upper and lower canines and upper and lower premolars, the minimum recommended space between adjacent crowns and roots for its safe placement is 7 mm. The minimal vertical space between the head of the implant and the opposing dentition for placement of a fixed restoration is also 7 mm. Orthodontic

procedures were used to increase the separation between the crowns and/or the adjacent teeth' roots to permit a dental implant's safe placement.<sup>11</sup>

We used a 3.0 x 13.0 mm Nobel Active Implant in this study. The mini dental implant provided favorable survival rates of 98.3% after 5 to 10 years. Therefore, it could be predictably employed for simplifying implant therapy in situations of reduced alveolar height in anterior areas. Vertical growth could be explained by the ossification of the periosteum or connective tissue, which lays directly on the bone surface. The process of bone remineralization and bone growth was encouraging because they indicate that some improvement can occur over time, even in cases of crestal bone loss or not.<sup>15</sup>

In this case, we used a bone level or subcrestal implant. Most implant companies recommended this position and may therefore be the position clinicians automatically presume to be the best. Some manufacturers suggested placing their implant 0.5 to 1.0 mm below bone level. An implant placed this deeply had bone loss and stability levels like those placed at the crest. Was leads to the question of exactly how deep implants should be placed, and the answers were not always straightforward. Remember that if tissue thickness is already sufficient, there is no



need to place implants subcrestally at all. Many authors recommended placing the implant at bone level subcrestally.<sup>16</sup>

The process of tissues becoming thicker can be explained by the development of biological width (BW) around implants. Logically, subcrestal placement makes sense as a solution because tissue increase with bone remodeling. For example, if the implant neck is placed 1.5 mm below the bone crest and vertical soft tissue thickness is 2 mm, there will be 3-5 mm of BW. It was sufficient for forming a peri-implant seal, avoiding bone resorption. Because the implants were placed more profoundly in the bone, the bone is in direct contact with the healing abutment. The position of the implant creates vertical walls of bone, sort like a tunnel, and this vertical distance becomes a crucial factor in the development of higher vertical tissue thickness. The space created by subcrestal implant placement is occupied by a blood clot, which is later reorganized into connective tissue. In other words, soft tissue ingrowth is very thin and extends in a vertical direction from the top of the bone to the neck of the implant. In this way, there is the elongation of soft tissue contact, i.e., vertical augmentation of the peri-implant seal, which results in biological protection of the implant.<sup>17</sup>

## **CONCLUSION**

Mini dental implants could be the treatment of choice for advanced cases of avulsion without bone augmentation. The last control shows the stability of soft and hard tissue.

## **CONFLICT OF INTEREST**

We declare no potential conflict of interest in the scientific articles we write.

## **ACKNOWLEDGEMENT**

Our thanks go to the professionals who assisted in the research and preparation of the paper.

## **REFERENCES**

1. Chesterman J. Chauhan R. Patel MWY. Chan F. The Management of Traumatic Tooth Loss with Dental Implants: Part 1. *British Dental Journal* 2014; 217: 627-633.
2. Murri DDA. Apponi R. Colombini V. Mordini L. Ideo F. Complex Implant-Prosthetic Rehabilitation Following Sports Trauma With 14 Years of Follow-Up: Case Report. *Dent. J.* 2021; 9: 6.
3. Seymour DW. Patei M. Carter L. Chan M. The Management of Traumatic Tooth loss With Dental Implants: Part 2. Severe Trauma. *British Dental Journal.* 2014; 217: 667-671.

4. Andre ML. Sadami SR. Mardas N. Donos N. Alveolar Ridge Preservation After Dental Extraction And before Implant Placement: A literature Review. Periodontology Unit, UCL Eastman Dental Institute, London Rev Odonto Cienc. 2011; 26(1).
5. Siddiqui AA. Sosovicka M. Goetz M. Use of Mini Implants for Replacement and Immediate loading Of 2 Single Tooth Restorations: Clinical Case Report. Journal of Oral Implantology. 2016; 32(2): 82-86.
6. Andreasen JO. Andreasen, FM. Andersson, L. Textbook and Color Atlas of Traumatic Injuries To The Teeth. US: Wiley Blackwell; 2019.
7. Jones LC. Dental Trauma. Oral Maxillofacial Surg Clin N Am; 2020.
8. Peery M. Holmes S. Atlas of Operative Maxillofacial Trauma Surgery Primary Repair of Facial Injuries. UK: Springer; 2004.
9. Owall B. Kayser AF. Carlsson GE. Prosthodontics—Principles and Management Strategies 2nd ed. 2004.
10. Gianetti L. Apponi R. Murri DDA, Mintrone F. Rehabilitation of A Patient with Mini Implants After Avulsion of the Upper Incisors: A 13- Year Follow Up. Dental Traumatology. 2020; 00:1-6.
11. Hobkrik JA. Watson RM. Searson LL. Introducing Dental Implants. UK: Churchill Livingstone; 2003.
12. Garg AK. Implant Dentistry a Practical Approach 2<sup>nd</sup> Ed. Missouri: Mosby Elsevier; 2010.
13. Soni R, Singh A, Vivek R, Baranwal H, Chaturvedi T, Srivastava A. Immediate implant placement in mandibular anterior region with dehiscence. J Dent Implant. 2013; 3(2): 177.
14. Qian J. Wennerberg A. Albrektsson T. Reasons for Marginal Bone Loss Around Oral Implants. Clin Implants Dent Relat Res. 2012; 23: 257-263.
15. Linkevicius T. 2019. Zero Bone Loss Concepts. Quintessence Publishing co. Inc 411 N Raddant Road Batavia.
16. Lang NP. Berglundh T. Working Group 4 of seventh European workshop on Periodontology, Perimplant diseases: where are we now? Consensus of the Seventh European Workshop on Periodontology. J Clin Periodontol. 2011; 38: 178-181.
17. Heitz MLJ, Mombelli A. the Theraphy of Periimplatitis: A Systematic review. Int J Oral Maxillofacial Implant. 2014; 29: 245-325.